

Early optic neuropathy during pegylated alfa 2-B interferon and ribavirin HCV treatment. A case report

Bogdan Augustin Chis¹, Cristina Nicula², Dan Dumitrascu¹

1) 2nd Department of Internal Medicine, Iuliu Hatieganu University of Medicine and Pharmacy, Cluj-Napoca, Romania

2) Ophthalmology Department, Iuliu Hatieganu University of Medicine and Pharmacy, Cluj-Napoca, Romania

Abstract

Introduction. Hepatitis C viral infection (HCV) represents an important health problem worldwide. Natural evolution, with its complications, remains a high cause of mortality and morbidity. Interferon (IFN) treatment, along with ribavirin (RBV), was for several years the standard of care. However, many adverse effects have been described during this therapy. We report a very elusive case of optic neuropathy.

Case report. We report the case of a female patient, 50 years old, who underwent pegylated IFN alfa 2B and RBV treatment for viral hepatitis C with low grade fibrosis, in a period when she was not qualified for free oral therapy (with direct acting agents according regulations in this country at that time). After 10 weeks of treatment, she experienced blurred vision and an optic neuropathy was diagnosed, attributed to the HCV. The symptoms and eye fundus alterations (hemorrhage, exudates) remitted after discontinuation of therapy.

Conclusion. IFN treatment remains an option for viral hepatitis, but the adverse effects are to be considered. Optic neuropathy can occur during the former standard of care HCV therapy. Patients submitted to IFN plus RBV therapy should be monitored for ocular adverse effects.

Keywords: optic neuropathy, pegylated IFN, ribavirin, hepatitis C virus

Introduction

Hepatitis C is a life threatening condition, with potentially deadly outcome if untreated. Up to 2% of the world population are infected, but less than half of them are aware of their condition, as studies show in the last years [1]. Around 400,000 patients die each year from HCV infection condition and complications. Screening tests have been validated and began to be commonly used a few years after “non-A non-B” hepatitis virus identification. Since its discovery in the 1980’s (although the disease has been described in the 1970’s as “non-A non-B hepatitis” [2]), a safe and risk free treatment has been a challenge. Its transmission remains at a high rate, the main routes being the intravenous drugs use, non sterile medical procedures or blood derivative products. Mother-to-child transmission or vertical transmission can be as low as 3.6%, with higher infection rates for the newborns from the highly viremic mothers [3].

Beside the complications caused by the natural evolution of viral infection

(cirrhosis, hepatocellular carcinoma), there are other conditions that develop or are associated with HCV infection: autoimmune diseases (Sjogren’s syndrome, autoimmune thyroiditis) hematological (thrombocytopenia, cryoglobulinemia), oncology (pancreatic cancer, lymphocytosis and lymphomas), neurological [4,5].

Efficient treatment options are now available worldwide, with sustained virologic response over 90-95% (depending on liver fibrosis score) for new antiviral medication treatment 8-12 weeks (NS3/NS4A inhibitors along with NS5A inhibitors; cytochrome P450 inhibitors can be added). Before the introduction of new therapies, IFN plus RBV was the standard of care. Although the sustained virologic response was over 50% overall, irrespective of genotype, the adverse effects of IFN related treatment were important. Flu-like syndrome (headache, myalgia, arthralgia, fever, nausea, fatigue) and even depression or suicide were not uncommon among IFN treated patients [6,7].

DOI: 10.15386/mpr-1316

Manuscript received: 21.02.2019

Accepted: 27.04.2019

Address for correspondence:
bogdan_a_chis@yahoo.com

Case report

We present the case of a 50 years old woman with HCV infection detected 2 years before, during a regular medical examination. The viral load at the moment was 37.640 UI/mL, and the estimated liver fibrosis was F0-F1 on Metavir scale (0.27 on FibroTest). The therapy was initiated after 6 months, when the estimated fibrosis was F2 Metavir on liver rigidity index at elastography, along with a viral load of 271.703 UI/mL. The treatment consisted on alpha 2-B pegylated IFN alpha 2B once a week and 1000 mg of RBV daily. At the one month and 3 months follow-up, the viral load was 257 UI/mL and undetectable, respectively. At that time, DAA therapy was available only for F3 and F4 fibrosis stages in this country.

The flu-like syndrome onset was 2 weeks after the treatment was started, with febrile response, headache, myalgia, arthralgia, fatigue, shortness of breath), weight loss (about 4 kilograms in 2 months), hair loss, chronic rhinitis aggravation.

Biological examinations at one month of therapy showed a slow decrease of red blood cells (from 4.200.000/ml down to 3.680.000) and hemoglobin levels (down to 10.5 g/dL from 11.7 g/dL). No other pathological values were found.

After 10 weeks of therapy, the patient experienced blurry vision, with grey spots in vision, more important in the left eye at first, but gradually in both eyes equally. Xerophthalmia and conjunctivitis symptoms (dry and red eyes) also appeared. Reading or writing, but also long distance view, became more difficult, as the vision adaptation became weaker. Also, the fever after the IFN alpha 2B injection became higher (up to 38.4 degrees Celsius).

The ophthalmologic examination after three months of treatment of IFN alpha 2B treatment revealed at the fundus examination of the right eye two flare hemorrhages on supero-temporal and exudates in infero-nasal arcade (Figure 1, 2).

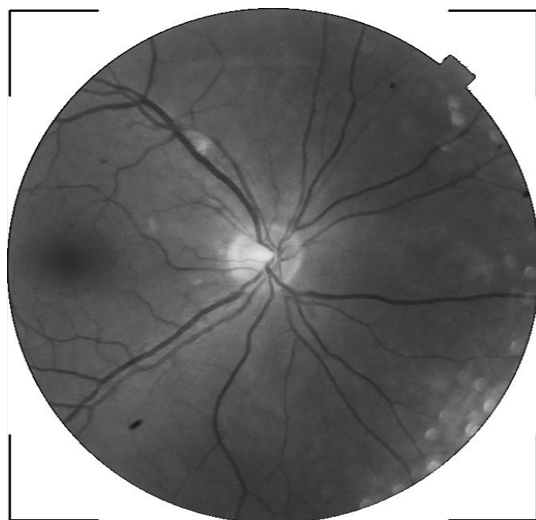


Figure 1. Right eye fundus examination.

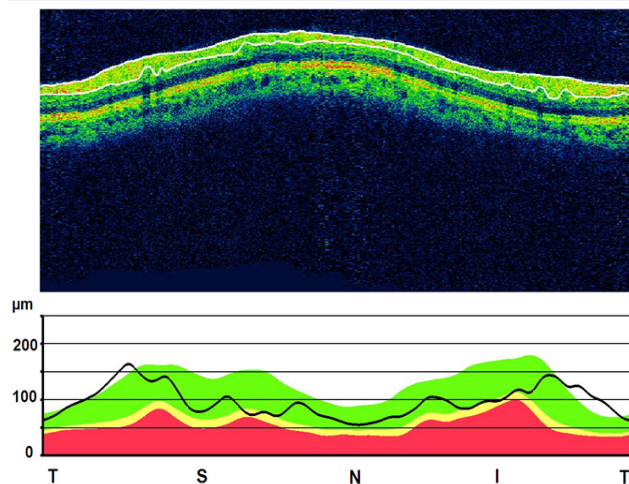


Figure 2. Retinal nerve fiber layer circular tomogram/thickness of the right eye (slightly lower thickness in superior and inferior areas).

At the left eye, on the supero-temporal branch, only two hard exudates and one soft exudate were found.

No visual field or intraocular pressure modifications were found. The case was interpreted as optic neuropathy. Antiplatelet (aspirin 75mg/day) and nicergoline (30 mg/day) treatment was initiated. At the 2 weeks follow-up, petechial hemorrhage was found in left supero-temporal branch area. As hemorrhage was found on both eyes, compared with previous examination, an IFN alpha 2B treatment involvement was suspected, so the antiviral treatment was interrupted. No other causes of ischemia were found (hypertension or hyperlipemia). After the IFN alpha 2B cessation, the vision improved and returned to normal in about one week. After one month, the eye fundus examination was almost normal. Antiplatelet and nicergolin treatment was continued for one month. After 6 months the viral load was 592 UI/mL, and the liver fibrosis was estimated at F1-F2 on Metavir scale (0.37 on FibroTest). The free IFN alpha 2B treatment is now considered for this patient, as the new antiviral medications are now available in all fibrosis stages in this country.

Discussion

Our patient had bilateral involvement of ischemic changes induced by IFN alpha 2B, which is quite rare in literature, compared to the increasing number of patients, with rapid and complete resolution after IFN alpha 2B treatment cessation. RBV was used along with IFN alpha 2B, but no significant ocular adverse effects were published yet in literature.

Pegylated IFN alpha 2B has been used for the treatment of viral hepatitis C since 2001, when it was approved by EMA, but also for melanoma, along with surgery. As the costs of free IFN treatment remains high, it still represents an option, along with RBV, in hepatitis C treatment. The sustained viral response can be up to

70-80% (depending on the genotype) [6]. Because of the adverse effects, only 75% of the patients will continue the treatment all the 48 weeks duration [8].

Beside peripheral neuropathy, optical involvement can appear (blurred vision, retinal involvement or high intraocular pressure). If not looked for (like eye fundus examination, as no guidelines for ophthalmologic consultations during IFN alpha 2B treatment are in place if not symptomatic), the changes can remain underdiagnosed, as they are often asymptomatic. Usual findings are cotton wool spots and hemorrhage, but ischemic lesions remain uncommon. Previous cases found in literature presented optical involvement from 3 weeks to 10 months of treatment, with visual acuity recovery in most of the cases [9]. Although IFN alpha 2B induced optic neuropathy was described, IFN alpha 2B cases were more frequent than beta (471 vs. 12 cases) [10].

The mechanism involved remains unclear. Hepatitis C induced immunity disorders and deposition of immune complexes (due to autoantibodies) in the retina could be responsible [11].

No specific treatment is available, but IFN alpha 2B cessation is recommended, and if needed, corticoids in severe nerve damage. Our patient's symptoms completely remitted after IFN cessation and antiplatelet with nicergolin supplementation.

References

1. GBD 2015 Disease and Injury Incidence and Prevalence, Collaborators. Global, regional, and national incidence, prevalence, and years lived with disability for 310 diseases and injuries, 1990-2015: a systematic analysis for the Global Burden of Disease Study 2015. *Lancet*. 2016;388:1545–1602.
2. Alter H. Discovery of non-A, non-B hepatitis and identification of its etiology. *Am J Med*. 1999;107(6B):16S-20S.
3. Syriopoulou V, Nikolopoulou G, Daikos GL, Theodoridou M, Pavlopoulou I, Nicolaidou P, et al. Mother to child transmission of hepatitis C virus: rate of infection and risk factors. *Scand J Infect Dis*. 2005;37:350-353.
4. Zignego AL, Ferri C, Pileri SA, Caini P, Bianchi FB; Italian Association of the Study of Liver Commission on Extrahepatic Manifestations of HCV infection. Extrahepatic manifestations of Hepatitis C Virus infection: a general overview and guidelines for a clinical approach. *Dig Liver Dis*. 2007;39:2–17.
5. Monaco S, Ferrari S, Gajofatto A, Zanusso G, Mariotto S. HCV-related nervous system disorders. *Clin Dev Immunol*. 2012;2012:236148.
6. Lin CC, Wu CH, Chen HL, Lin IT, Wang SY, Wang TE, et al. Peginterferon alpha-2b plus ribavirin for chronic hepatitis C virus mixed genotype infection. *Ann Hepatol*. 2014;13:350-355.
7. Lucaciu LA, Dumitrascu DL. Depression and suicide ideation in chronic hepatitis C patients untreated and treated with interferon: prevalence, prevention, and treatment. *Ann Gastroenterol*. 2015;28:440-447.
8. Gidding HF, Law MG, Amin J, Ostapowicz G, Weltman M, Macdonald GA, et al. Hepatitis C treatment outcomes in Australian clinics. *Med J Aust*. 2012;196:633-637.
9. Berg KT, Nelson B, Harrison AR, McLoon LK, Lee MS. Pegylated interferon alpha-associated optic neuropathy. *J Neuroophthalmol*. 2010;30:117-122.
10. Fragoso YD, Paggiaro MS, Mastromauro R, Jacondino Gda S, Wilson HM. Literature systematic review on the ophthalmological side effects of interferons. *Arq Bras Oftalmol*. 2011;74:306-310.
11. Lohmann CP, Kroher G, Bogenrieder T, Spiegel D, Preuner J. Severe loss of vision during adjuvant interferon alfa-2b treatment for malignant melanoma. *Lancet*. 1999;353:1326.