

CASE REPORT OF PRIMARY SMALL CELL NEUROENDOCRINE BREAST CANCER

EMIL PUSCAS^{2,3}, COSMIN LISENCU², IOANA NEAGOE¹

¹Department of Functional Genomics and Experimental Pathology, The Oncology Institute “Prof. Dr. Ion Chiricuță”, Cluj-Napoca, Romania

²Department of Oncological Oncology and Surgical Oncology, The Oncology Institute “Prof. Dr. Ion Chiricuță”, Cluj-Napoca, Romania

³Iuliu Hațieganu University of Medicine and Pharmacy, Cluj-Napoca, Romania

Abstract

Primary neuroendocrine cancer of the breast (NECB) is an extremely rare tumor. In 2003, the World Health Organization (WHO) recognized this category with three well-described subtypes: small cell, large cell, and carcinoid-like carcinoma; very few peer-review publications based on the WHO definition were encountered in the literature, and we conducted a literature search to investigate the reported incidence, diagnosis, prognosis, hormone receptor status, and treatment options for this rare tumor. Confirming the breast as an origin of neuroendocrine tumor represents a challenge. The diagnosis is mainly dependent on the exclusion of other extra-mammary organs based on clinical, radiological, and pathological data.

Primary neuroendocrine carcinoma of the breast is rare - only about 30 cases have been reported in literature. Immunohistochemical examination showing expression of chromogranin and/or synaptophysin confirms evidence of neuroendocrine differentiation. Usually foci of neuroendocrine differentiation can be seen in breast carcinoma and are reported to be present in about 2-5% of breast cancer cases. Here, we report a case of breast carcinoma in which most of the areas studied on the tissue section showed neuroendocrine differentiation.

Primary neuroendocrine carcinoma of the breast is a group that exhibits morphological features similar to those of neuroendocrine tumors of both the gastrointestinal tract and the lung.

Case presentation

We report the case of a 50-year-old Caucasian woman with primary small cell neuroendocrine cancer of the breast, which we characterized with immunohistochemical techniques. A palpable and mobile 3.0 cm tumor was located in the upper-outer quadrant of her right breast. After pathological confirmation the patient underwent 8 cycles of chemotherapy, and subsequent radical mastectomy with axillary lymph node resection were performed. Microscopically, the tumor consisted predominantly of a diffuse proliferation of small oat cells. The tumor cells were positive for neuroendocrine markers; 21 of 30 lymph nodes were metastatic.

Local recurrence with multiple lung metastases developed only 5 weeks after surgery, despite of the transient tumor regression achieved by chemotherapy. This case reinforces the importance of an early correct diagnosis and the standardization of a treatment regimen for this very rare tumor.

A correct treatment needs to be chosen.

Keywords: breast cancer, primary small cell neuroendocrine breast cancer, treatment, dissemination.

Introduction

Primary neuroendocrine cancer of the breast (NECB) is an extremely rare tumor. In 2003, the World Health Organization (WHO) recognized this category with three well-described subtypes: small cell, large cell, and carcinoid-like carcinoma.

Extrapulmonary small-cell neuroendocrine carcinomas account for 2.5%-5% of all small-cell neuroendocrine carcinomas [1].

Neuroendocrine small cell carcinoma with features indistinguishable from pulmonary small cell carcinoma can occur in a variety of extrapulmonary sites. These tumors have been reported in the breast, larynx, trachea, stomach, small intestine, bladder prostate, cervix, ovary and many other organs and tissues [2-5].

Contrary to pulmonary small cell carcinomas, extra pulmonary tumors of this type are very uncommon. Reports also suggest that clinical course of extrapulmonary SCNC is as aggressive as its pulmonary counterpart [6,7].

Since its first description by Wade et al. in 1983, we were able to find only 35 recorded cases in literature (Table I) [8-27].

Case report

A 53 year old female patient was admitted to the

Cluj-Napoca Institute of Oncology with a palpable mass in her right breast for specialty treatment.

On examination the right breast showed a mass of about 12 cm in diameter in the lower-inner and intern quadrants. She had a 3 cm ipsilateral axillary lymphadenopathy. The left breast examination and other clinical examinations were within normal limits.

Mammography and echography revealed suspicious characteristics in the nodule (Figures 1&2).

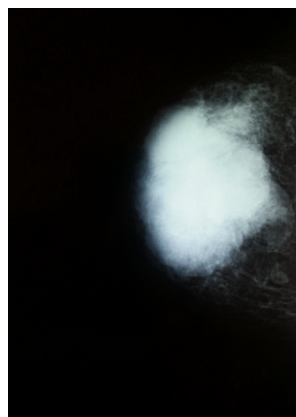


Figure 1.

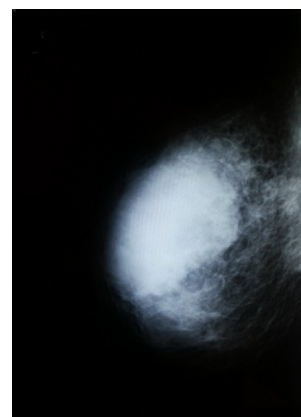


Figure 2.

Table I. Published case reports of neuroendocrine carcinoma of the breast.

No.	First author [Ref]	Year	Age/Sex	TNM	Size (mm)	IS	Treatment	Follow-up (months)	Outcome
1	Wade [8]	1983	52/F	T4N1M1	100	-	MRM/CT	9	DOD
2	Jundt [9]	1984	52/M	T _x N1M _x	NS	-	CT/RT	14	DOD
3	Papotti [10]	1992	64/F	T1N0M0	20	+	SRM	44	NED
4		1992	41/F	T2N1M0	35	+	SRM/RT	15	DOD
5		1992	50/F	T2N1M0	30	+	SRM	14	DOD
6		1992	69/F	T3N1M0	50	+	MRM	9	DUD
7	Francois [11]	1995	68/F	T2N0M0	40	-	MRM/RT	21	DUD
8	Chua [12]	1997	45/F	T2N0M _x	45	NS	TR	NS	NS
9	Fukunaga [13]	1998	56/F	T4N1M _x	100	+	SRM	48	NED
10	Yamasaki [14]	2000	41/F	T2N0M0	45	+	MRM/CT	16	NED
11	Shin [15]	2000	43/F	T1N _x M0	13	*	BCS/RT	30	NED
12		2000	44/F	T1N0M0	20	*	BCS/CT/RT	27	NED
13		2000	46/F	T2N1M0	34	*	MRM/CT	11	AWD
14		2000	50/F	T2N1M0	22	*	BCS/CT	35	NED
15		2000	51/F	T1N0M0	15	*	BCS/RT	25	NED
16		2000	57/F	T2N0M0	25	*	MRM/CT	10	NED
17		2000	62/F	T2N0M0	50	*	NAC/MRA/CT	32	AWD
18		2000	64/F	T1N0M0	18	*	TR/CT	10	NED
19		2000	70/F	T2N1M0	40	*	BCS	3	NED
20	Samli [16]	2000	60/F	T4N1M0	80	-	NAC/MRM/CT/RT	6	AWD
21	Salmo [17]	2001	46/F	T2N0M0	40	+	TR/CT/RT	9	NED
22	Hoang [18]	2001	41/F	T _x N _x M _x	145	+	NS	NS	NS
23		2001	51/F	T _x N _x M _x	80	+	NS	NS	NS
24	Bergman [19]	2004	61/F	T2N1M0	25	+	MRM	NS	NS
25	Sridhar [20]	2004	58/F	T1N1M0	20	-	BCS/CT/RT	18	NED
26	Bigotti [21]	2004	56/F	T3N1M0	180	+	NAC/SRM/CT	14	DOD
27	Jochims [22]	2004	71/F	T2N0M0	30	-	MRM	12	NED
28	Yamamoto [23]	2004	53/F	T3N2M0	65	NS	NS	34	NED
29		2004	75/F	T2N1M0	25	NS	NS	43	NED
30	Adegbola [24]	2005	46/F	T1N0M0	10	-	TR/CT/RT	48	NED
31		2005	60/F	T1N0M0	17	+	TR/CT/RT	20	DOD
32		2005	61/F	T1N1M0	17	-	TR/CT/RT	6	AWD
33	Stein [25]	2005	54/F	T1N1M0	20	NS	NAC/MRM/RT	24	NED
34	Salman [26]	2006	NS/F	T2N _x M0	50	+	NAC/MRM	NS	NS
35	Kinoshita [27]	2008	31/F	T3N1M0	60	+	NAC/MRM/CT	6	DOD
	Present case	2012	53/F	T4N3M1	110	-	NAC/MRM/RT-CT	9	AWD

A core biopsy revealed a solid small-cell neuroendocrine carcinoma, G III with negative estrogen and progesterone receptors. IHC: CK AE1/AE3 positive, CD56 positive, TTF1 negative, chromogranin and synaptophysin negative.

CT/MRI scans of the lung, abdomen and bone were normal.

Confirming the breast as an origin of neuroendocrine tumor represents a challenge. The diagnosis is mainly dependent on the exclusion of other extramammary organs based on clinical, radiological, pathological and IHC data.

In conclusion Small-cell neuroendocrine breast cancer - T4bN2M0.

The patient underwent neo-adjuvant chemotherapy, 4 cycles: Farmorubicin 100 mg/mp DT = 165 mg; Ciclofosfamida 600 mg/mp DT = 980 mg and 4 cycles: Taxotere 75 mg/mp DT = 125 mg.

Partial result was achieved after neo-adjuvant therapy, the tumor being reduced to 5 cm in diameter. Again the CT/MRI scans were normal.

Subsequently the patient underwent a right radical mastectomy with axillary lymph node resection. Macroscopically, the tumor was 4-5 cm in maximum diameter. Widespread vascular invasion was present; 21 of 30 lymph nodes were metastatic.

It was decided by a multi disciplinary team that adjuvant radiotherapy was needed.

Eight months after diagnosis and one month after MRM the patient presented signs of local recurrence in the form of permeation nodules. After skin biopsy the diagnosis was confirmed.

After other investigations, CT, Rx lung and liver metastasis were discovered.

Radiotherapy was started along with hyperthermia and a new chemotherapy regime was considered.

The study was performed with the patient's consent and the approval of the hospital's ethic committee.

Discussion

Small cell neuroendocrine breast cancer is generally characterized by early dissemination and a rapid, aggressive clinical course. However, the biological behaviour of mammary SmCC is still uncertain because this type of breast tumor is less frequently encountered. There are several reports, which consist largely of case reports, and these reported patients showed a relatively poor prognosis with a more advanced stage at diagnosis [28-30]. The stage of the disease at the time of diagnosis is an important determining factor of the prognosis [31].

Conclusion

Treatment for the SmCC of the breast has not yet been established, and a consensus has yet to be reached. It is clear that more studies are needed in order to achieve an

effective treatment. Unfortunately cases are very rare and their evolution very poor, making it difficult to come up with a proper treatment.

References

1. Frazier SR, Kaplan PA, Loy TS. The pathology of extrapulmonary small cell carcinoma. *Semin Oncol*, 2007; 34:30-38.
2. Richardson RL, Weiland LH. Undifferentiated small cell carcinomas in extrapulmonary sites. *Semin Oncol*, 1982; 9:484-485.
3. Samli B, Celik S, Evrensel T, et al. Primary neuroendocrine small cell carcinoma of the breast. *Arch Pathol Lab Med*, 2000; 124:296-298.
4. Ibrahims NBN, Briggs JC, Corbishley CM. Extrapulmonary oat cell carcinoma. *Cancer*, 1984; 54:1645-1661.
5. Shin SJ, DeLellis RA, Ying L, et al. Small cell carcinoma of the breast: a clinicopathologic and immunohistochemical study of nine patients. *Am J Surg Pathol*, 2000; 24:231-238.
6. Yamasaki T, Shimazaki H, Aida S, et al. Primary small cell (oat cell) carcinoma of breast: report of case and review of literature. *Pathol Int*, 2000; 50:914-918.
7. Sapino A, Righi L, Cassoni P, et al. *Semin Diagn Pathol*, 2000; 17:17-37.
8. Wade PM Jr, Mills SE, Read M, Cloud W, Lambert MJ, Smith RE. Small cell neuroendocrine (oat cell) carcinoma of the breast. *Cancer*, 1983; 52:121-125.
9. Jundt G, Schulz A, Heitz PU, Osborn M. Small cell neuroendocrine (oat cell) carcinoma of the male breast. *Virchows Arch A Pathol Anat Histopathol*, 1984; 404:213-221.
10. Papotti M, Gherardi G, Eusebi V, Pagani A, Bussolati G. Primary oat cell (neuroendocrine) carcinoma of the breast. *Virchows Arch A Pathol Anat Histopathol*, 1992; 420:103-108.
11. Francois A, Chatikhine VA, Chevallier B, et al. Neuroendocrine primary small cell carcinoma of the breast. *Am J Clin Oncol*, 1995; 18:133-138.
12. Chua RS, Torno RB, Vuletin JC. Fine needle aspiration cytology of small cell neuroendocrine carcinoma of the breast. *Acta Cytol*, 1997; 41:1341-1344.
13. Fukunaga M, Ushigome S. Small cell (oat cell) carcinoma of the breast. *Pathol Int*, 1998; 48:744-748.
14. Yamasaki T, Shimazaki H, Aida S, et al. Primary small cell (oat cell) carcinoma of the breast: Report of a case and review of the literature. *Pathol Int*, 2000; 50:914-918.
15. Shin SJ, DeLellis RA, Ying L, Rosen PP. Small cell carcinoma of the breast. A clinicopathologic and immunohistochemical study of nine patients. *Am J Surg Pathol*, 2000; 24:1231-1238.
16. Samli B, Celik S, Evrensel T, Orhan B, Tasdelen I. Primary neuroendocrine small cell carcinoma of the breast. *Arch Pathol Lab Med*, 2000; 124:296-298.
17. Salmo EN, Connolly CE. Primary small cell carcinoma of the breast: report of a case and review of the literature. *Histopathology*, 2001; 38:277-278.
18. Hoang MP, Maitra A, Gazdar AF, Albores-Saavedra J. Primary mammary small-cell carcinoma: a molecular analysis of 2 cases. *Hum Pathol*, 2001; 32:753-757.
19. Bergman S, Hoda SA, Geisinger KR, Creager AJ, Trupiano JK. E-cadherin-negative primary small cell carcinoma of the breast. *Am J Clin Pathol*, 2004; 121:117-121.
20. Sridhar P, Matery P, Aluwihare N. Primary carcinoma of the

- breast with small-cell differentiation. *Breast*, 2004; 13:149-151.
21. Bigotti G, Butti A, del Vecchio M, Tartaglione R, Massi G. Primary small cell neuroendocrine carcinoma of the breast. *J Exp Clin Cancer Res*, 2004; 23:691-696.
 22. Jochems L, Tjalma WAA. Primary small cell neuroendocrine tumor of the breast. *Eur J Obstet Gynecol Reprod Biol*, 2004; 115:231-233.
 23. Yamamoto J, Ohshima K, Nabeshima K, Ikeda S, Iwasaki H, Kikuchi M. Comparative study of primary mammary small cell carcinoma, carcinoma with endocrine features and invasive ductal carcinoma. *Oncol Rep*, 2004; 11:825-831.
 24. Adegbola T, Connolly CE, Mortimer G. Small cell neuroendocrine carcinoma of the breast: a report of three cases and review of the literature. *J Clin Pathol*, 2005; 58:775-778.
 25. Stein ME, Gershuny A, Abdach L, Quigley MM. Primary small cell carcinoma of the breast. *Clin Oncol*, 2005; 17:201-202.
 26. Salman WD, Harrison JAF, Howat AL. Small-cell neuroendocrine carcinoma of the breast. *J Clin Pathol*, 2006; 59:888.
 27. S. Kinoshita, et al. Small-Cell Carcinoma of the Breast. *Surg Today*, 2008; 38:734-738.
 28. Richardson RL, Weiland LH. Undifferentiated small cell carcinomas in extrapulmonary sites. *Semin Oncol*, 1982; 9:484-496.
 29. Samli B, Celik S, Evrensel T, Orhan B, Tasdelen I. Primary neuroendocrine small cell carcinoma of the breast. *Arch Pathol Lab Med*, 2000; 124:296-298.
 30. Francois A, Chatikhine VA, Chevallier B, et al. Neuroendocrine primary small cell carcinoma of the breast. Report of a case and review of the literature. *Am J Clin Oncol*, 1995; 18:133-138.
 31. Adegbola T, Connolly CE, Mortimer G. Small cell neuroendocrine carcinoma of the breast: a report of three cases and review of the literature. *J Clin Pathol*, 2005; 58:775-778.