



ONCOLOGY

Mucinous cystic neoplasm of the liver (MCN-L): a rare presentation and review of the literature

Sweta Soni¹, Puneet Pareek¹, Satya Narayan¹, Vaibhav Varshney²

1) Department of Radiation Oncology, All India Institute of Medical Sciences, Rajasthan, India

2) Department of Gastrointestinal Surgery, All India Institute of Medical Sciences, Jodhpur, Rajasthan, India

Abstract

Mucinous cystic neoplasms of the liver (MCN-L, (previously referred to as cystadenomas or cystadenocarcinoma) are rare cystic tumors that occur within the liver parenchyma, or less frequently, in the extrahepatic bile ducts. They are reported to account for <5% of all liver cysts. The differential diagnosis of MCN-L includes intraductal papillary neoplasm of the bile duct (IPNB), intrahepatic cholangiocarcinoma with cystic change, echinococcal cyst, and a simple cyst. Invasive MCNs can only be differentiated from non-invasive MCNs by microscopic evaluation for the presence of ovarian-type stroma. Intraoperative biopsy and frozen section(s) are essential to differentiate MCNs from other cystic liver lesions. The treatment of choice is complete excision and can result in excellent survival with initial correct diagnosis. But its rare presentation and insufficient recognition frequently lead to an incorrect initial or delayed diagnosis or misdiagnosis.

Keywords: liver, mucinous cystic neoplasms, cystadenoma, differential diagnosis

Introduction

Cystic lesions of the liver represent a heterogeneous group of disorders, which differ in etiology, prevalence, and clinical manifestations (Table I). Most liver cysts are found incidentally on imaging studies and tend to have a benign course. A minority can cause symptoms and rarely may be associated with serious morbidity and mortality [1,2].

Mucinous cystic neoplasms of the liver (MCN-L) are rare entities. Previously, these lesions have been

reported under the general terms of "biliary cystadenoma" and "biliary cystadenocarcinoma". However, this lesion type was redefined and classified by the World Health Organization (WHO) in 2010 and is now defined as "a cyst forming epithelial neoplasm, usually with no communication with the bile ducts, composed of cuboidal to columnar, variably mucin-producing epithelium, associated with ovarian-type subepithelial stroma" and is subdivided into non-invasive and invasive types [3].

Table I. Classification of hepatic cysts.

Simple (solitary) cyst
Polycystic disease
Parasitic:
Hydatid (echinococcal)
Neoplastic
Primary: Cystadenoma, cystadenocarcinoma, squamous cell carcinoma
Secondary: Carcinoma of ovary, pancreas, colon, kidney, neuroendocrine
Duct related:
Caroli's disease
Bile duct duplication
False cyst:
Traumatic intrahepatic hemorrhage
Intrahepatic infarction
Intrahepatic biloma
Ciliated foregut cyst

DOI: 10.15386/mpr-1543

Manuscript received: 09.12.2019

Received in revised form: 19.01.2020

Accepted: 06.02.2020

Address for correspondence:
sonisweta@hotmail.com

This work is licensed under a Creative Commons Attribution-NonCommercial-NoDerivatives 4.0 International License

Case Report

The treatment of choice for both non-invasive and invasive MCN is surgical excision, but resectability is dependent on the anatomic location of the tumor, functional liver reserve and medical comorbidities. However because of its rare presentation it is often misdiagnosed. In this case report we try to emphasize on presentation, diagnosis, treatment and outcomes of MCN-L.

Case Report

Fifty five years old woman with no-comorbidities and addiction, presented with complaints of dull aching pain in the right hypochondrial region on and off for the past 5 months. Ultrasound of whole abdomen was done to identify possible cause. It was suggestive of mild hepatomegaly with 14 x 12.5 cm sized cystic lesion seen in the liver, suspicious for hydatid cyst. Later, ELISA (enzyme linked immune-sorbent assay) for echinococcus granulosus / hydatid serology was done and was reported negative. Routine laboratory studies such as complete hemogram, liver function test and renal function test were within normal limits and viral markers, namely Human Immunodeficiency Virus (HIV), Hepatitis B Surface Antigen (HBsAg) and Hepatitis C Virus (HCV) were non-reactive. Contrast enhanced computed tomography (CECT) abdomen was suggestive of large cystic lesion size 12.4 x 12.1 x 13.6 cm noted in hilum of the liver compressing biliary confluence resulting in minimal

dilatation of IHBR (intra hepatic biliary radicles) and also compressing portal bifurcation and gall bladder with lateral displacement but no surrounding infiltration was seen (Figure 1). MRCP (Magnetic Resonance Cholangiopancreatography) evidenced well defined unilocular cyst 14 x 12 cm in the left lobe of the liver causing mass effect which is seen as rightward displacement and compression of gall bladder. The cyst shows thin peripheral septation without any hemorrhage or calcification. Mild IHBR dilatation is seen in the left lobe. No overt communication was seen with the biliary duct, right and left portal vein, while right and left hepatic ducts were splayed by the cyst. Laparoscopic deroofting of cyst with drainage was done. The histopathological examination revealed cyst lined by single layer of bland, cuboidal to low columnar mucinous epithelium; the mucinous epithelium showed no high-grade dysplasia or malignancy. The underlying stromas composed of fibrocollagenous tissue with collections of histiocytes along with densely packed spindle cells, histologically mimicking ovarian-type stroma (Figure 2). Granulation tissue along with focal fibrinous exudate was also seen. No hydatid cyst was seen. Scanty part of liver tissue was seen. Final impression by pathologist was non-invasive mucinous cystic neoplasm of the liver. Three months after surgery, abdominal CECT was suggestive of no residual lesion. At 6 months and 12 months of follow-up, the patient is well and free of symptoms.

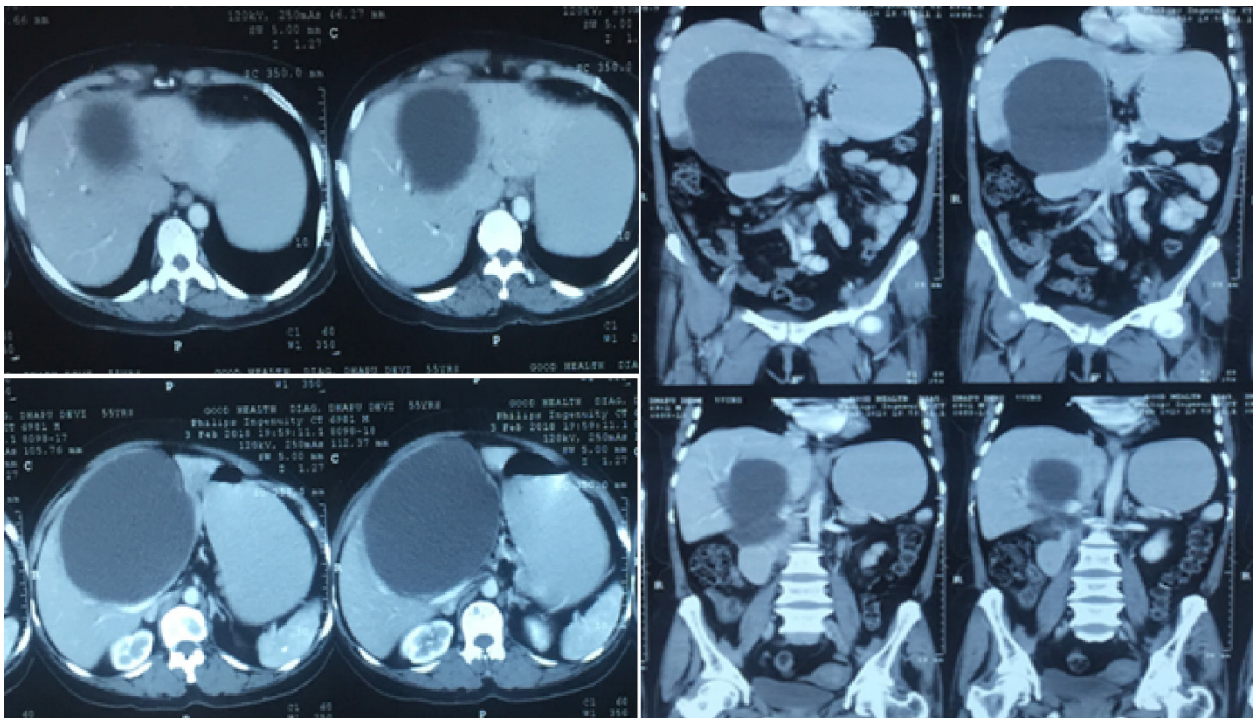


Figure 1. CECT abdomen: well-defined unilocular cyst 14 x 12 cm noted in left lobe of liver causing mass effect which is seen as rightward displacement and compression of gall bladder.

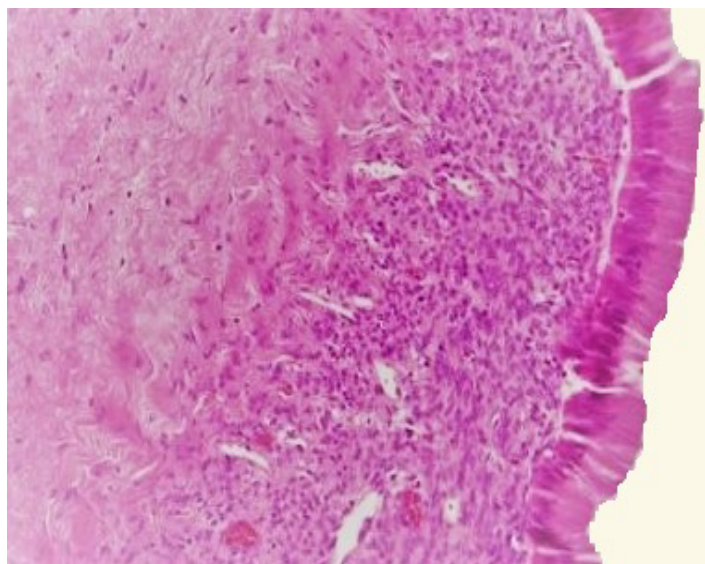


Figure 2. Histopathology findings: cyst lined by layer of bland, cuboidal to low columnar mucinous epithelium. The underlying stromas composed of fibrocollagenous tissue with collections of histiocytes along with densely packed spindle cells, histologically mimicking ovarian-type stroma.

Discussion

Mucinous cystic neoplasms of the liver (MCN-L; previously referred to as cystadenomas or cystadenocarcinoma) are rare cystic tumors that occur within the liver parenchyma, or less frequently, in the extrahepatic bile ducts. They are reported to account for <5% of all liver cysts [3,4]. The vast majority of these tumors occur in women, generally in the fifth and sixth decades [5].

Imaging

On ultrasonography, an MCN typically appears as a hypochoic lesion with thickened, irregular walls and occasional internal echoes representing debris and wall nodularity. These findings are generally indicative of a complicated cyst, which may represent a simple cyst with previous bleeding, a neoplastic cyst such as an MCN (with or without invasive carcinoma), or rarely, a metastasis. On

a computed tomography scan, an MCN appears as a low attenuation mass, which may be uni- or multilocular or may have septations. The cyst wall is usually thickened and/or irregular. This is in contrast to a simple cyst, which is typically devoid of septations and has imperceptible walls (Table II).

MRI (magnetic resonance imaging) is another useful tool in evaluation. MRI characterizes cyst fluid content by varying signal intensities on T1 weighted images depending on cyst fluid protein content. Linear low signal intensity within high intensity cysts identifies septations on T2 weighted images [6]. On DW-MRI (diffusion weighted magnetic resonance imaging), the hepatic abscesses show marked hyperintensity, whereas the necrotic portions of the cystic or necrotic tumors show hypointensity. DW-MRI and ADC (apparent diffusion coefficient) maps may be a useful noninvasive imaging technique in differentiating hepatic abscesses from cystic or necrotic liver tumors [7].

Table II. Radiologic features of hepatic cyst.

Hepatic/ biliary cystic tumours	Hepatic simple cysts	Echinococcal cysts
Multiloculated cyst	Anechoic	
Internal septation	Smooth borders	
Enhancing cyst wall	No perceptible wall	Daughter cyst within main cyst
Calcifications	No septations	Intracystic debris
Papillary wall nodules	No enhancement on CT with IV contrast	Low signal intensity rim on T2-weighted MRI
Thickened irregular wall	Water attenuation on CT	
Enhancement on CT with IV contrast		
Water attenuation on CT		

MRCP (magnetic resonance cholangiopancreatography) can also be helpful in that it can demonstrate cyst communication with the biliary tree as well as identify internal septations. MRCP can better visualize the biliary tree proximal to an obstruction, unlike ERCP (Endoscopic Retrograde Cholangio-Pancreatography) [8]. ERCP is uncommonly utilized for biliary cystic tumour, but in select circumstances may be helpful in obtaining tissue samples, identifying biliary tree communications, and extrahepatic biliary cystic tumours [6,8].

Differential Diagnosis

The World Health Organization (WHO) classification of 2010 defined MCN-L as a counterpart of MCN of the pancreas (MCN-P) [3]. Similar to MCN-P, MCN-L is a multiloculated cystic tumor lined by mucus-secreting cuboidal or columnar epithelium with septae, cellular (mesenchymal) stroma resembling ovary, beneath the epithelium, usually showing no communication with the bile duct, and the presence of mural nodules and papillary projections is considered to constitute evidence of malignancy [3,4,9]. The differential diagnosis of MCN-L includes intraductal papillary neoplasm of the bile duct (IPNB), intrahepatic cholangiocarcinoma with cystic change, echinococcal cyst, and a simple cyst. The characteristic findings of IPNB, including communication with the bile ducts, bile duct dilatation, and papillary projections in the bile ducts, are useful for the diagnosis of MCN-L [3,10].

However, differential diagnosis between MCN-L and cyst-forming IPNB is difficult. In such cases, the presence of ovarian-like stroma is required to establish the diagnosis of MCN-L [4,11,12]. Shiono et al. [9] reported MCN in various organs (pancreas, liver, spleen, mesenterium), with ovarian-like stroma as the common clinico-pathological feature. However, it is still unclear whether the biological characteristics of MCN-L are similar to those of MCN-P, because MCN-L is a rare entity. Echinococcal cysts are frequently associated with calcifications, and patients will have positive serology. Simple cysts can usually be distinguished because of the absence of septations and papillary projections and the presence of serous cystic fluid.

Pathophysiology

Mucinous cystic neoplasms are slow-growing, they frequently reach a large size, and can progress over a period of years to invasive carcinoma. The presence of ovarian stroma in MCNs suggests a correlation with ovarian MCNs and has led to the hypothesis of an embryonal origin [13]. It has been suggested that the close proximity of the liver and gonads during embryonic development is responsible for the migration of gonadal cells into the liver surface and the resultant ovarian stroma in these lesions [13,14]. Further, the peritoneal surface epithelium of the embryonic gonads has been found to be lined with bulging cells as opposed to the typical flattened celomic epithelium. The examination of

embryos suggests that during the embryonic period, these bulging cells detach and migrate into the surfaces of nearby organs such as the liver [14].

Morphologically, invasive MCN differs from non-invasive MCN in that cellular pleomorphism, anaplasia and infiltration of the underlying fibrous stroma are present in invasive MCN, but absent from non-invasive MCN. The lining cells of the cyst show considerable variation in size and atypia in their nuclei, as well as loss of polarity [15,16]. More simply, although extensive infiltration of mucin-producing adenocarcinoma can be found in the walls of the cyst, there can also be occasional patches of lining that are benign and consist of a single layer of cuboid to columnar epithelium. In the variant in which mesenchymal ("ovarian like") stroma is present, it is visualized between an inner epithelial lining and an outer connective tissue capsule [17]. Papillary projections of the epithelial cells are also common. Invasive MCN is noted to be strongly reactive for cytokeratins 7,8,18 and 19, and epithelial membrane antigen (EMA) [3,18]. Focal expression of carcinoembryonic antigen (CEA) and CA19.9 can also be seen (particularly if there is an associated invasive carcinoma), but CEA and alpha-fetoprotein (AFP) are usually normal [3,19]. In a light microscopic and immunohistochemical study of 70 patients with non-invasive and invasive MCNs, conducted by Devaney et al., immunohistochemistry did not yield a diagnostic immunoprofile with which to distinguish non-invasive MCN from invasive MCN or from other epithelial lesions arising within the abdominal cavity [20].

It should be noted that the histologic features of intrahepatic MCNs parallel those of their pancreatic, ovarian and retroperitoneal counterparts. Notably, all these tumors lack communication with the duct system and contain mucin-producing epithelium [14]. In comparison with MCNs of the pancreas, intrahepatic MCNs more commonly have cuboidal, non-mucinous epithelium.

It is imperative to remember that, as previously indicated with reference to the differential diagnosis, a liver abscess can mimic a non-invasive MCN and even when there is clinical suspicion, and aspiration may not yield a correct diagnosis, especially in the chronic phase. Yamamoto et al. reported a patient with a cystic liver lesion in whom negative cytology and cultures grossly appeared to indicate a solid lesion, but whose final diagnosis indicated a chronic liver abscess [21]. This also further emphasizes that gross features alone are not sufficiently reliable to enable the definitive diagnosis of a MCN.

Treatment

The preferred treatment for cystadenomas is resection whenever possible, because malignant transformation of the cyst lining may occur over time. Partial excision in both cystadenoma and cystadenocarcinoma is invariably associated with recurrence and with worse prognosis compared with complete resection (Table III) [13,17,22-25].

Table III. Literature review and treatment outcomes.

Article	Patients (n)	Treatment	Outcome
Vogt et al. [14] 2005	n=22 ni-MCN:18 i-MCN:4 4 females Mean age: 60 years	ni-MCN 13 complete resections 5 partial excisions i-MCN 1 Enucleation 3 Anatomical resection	ni-MCN No perioperative deaths 13/13 patients with complete resection Follow-up: 1 month to 11 years i-MCN No peri-operative deaths 2 died of metastatic disease within 1 year 1 alive and NED at 16 years 1 alive with metastatic disease at 10 years
Lee et al. [24] 2009	n=10 ni-MCN:6 5 females Mean age: 45.3 years i-MCN:4 2 females Mean age: 62 years	8 anatomic resections 2 non-anatomic resections	No perioperative mortalities Mean follow-up: 82.6 months with 80% still alive with NED 2 with i-MCN died
Erdogan et al. [10] 2010	n=15 ni-MCN:12 i-MCN:3 13 females Mean age: 45 years	6 anatomic resections 9 cyst enucleations	No perioperative mortalities Long term survival NR
Emre et al. [20] 2011	n=9 ni-MCN:8 i-MCN:1 All female Mean age: 49years	ni-MCN 3 enucleations 3 major hepatectomies 2 non-anatomic resections i-MCN 1left hepatectomy	No perioperative mortalities reported No recurrences during a median follow-up of 31 months (range: 7–72 months)

i-MCN: invasive mucinous cystic neoplasm; ni-MCN: non-invasive mucinous cystic neoplasm, NED: no evidence of disease

Reported recurrence rates following complete surgical excision vary between 10% and 13%, but can be affected by study sizes that are frequently small as a result of the rarity of these tumors [26,27]. Unlike other primary hepatic tumors, systemic therapies have not been found to be particularly effective in the treatment of primary invasive MCN.

Conclusion

Mucinous cystic neoplasms of the liver (MCN-L) are rare cystic tumors that occur within the liver parenchyma and account for <5% of all liver cysts. Its rare presentation and insufficient recognition frequently leads to delayed diagnosis or is often misdiagnosed. Preoperative differential workup of a cystic liver tumor should always include MCN. Complete excision of a suspected non-invasive or invasive MCN of the liver is clearly the treatment of choice when the patient is medically fit for surgery and there is no evidence of systemic disease on initial workup. Survival rates and prognosis will become more defined as MCNs are resected with increased frequency and the appropriate classification is applied.

References

1. Benhamou JP, Menu Y. Non-parasitic cystic diseases of the liver and intrahepatic biliary tree. In: Blumgart LH, ed. Surgery of the liver and biliary tract. 2nd ed. New York: Churchill Livingstone Inc; 1994: p.1197-1210.
2. Gadzije E, Dragan S, Verica FM, Jana G. Hepatobiliary cystadenoma protruding into the common bile duct, mimicking complicated hydatid cyst of the liver. Report of a case. Hepatogastroenterology. 1995;42:1008-1010.
3. Tsui WMS, Adsay NV, Crawford JM, Hruban R, Kloppel G, Wee A, editors. WHO classification of tumors of the digestive system. 4th ed. Lyon: WHO; 2010. p. 236-238.
4. Simo KA, Mckillop IH, Ahrens WA, Martinie JB, Iannitti DA, Sindram D. Invasive biliary mucinous cystic neoplasm: a review. HPB (Oxford). 2012;14:725-740.
5. Valasek M, Yeh M. Mucinous Cystic Neoplasm of the Liver: Clinicopathologic Features and Differential Diagnosis case review. Pathology Case Reviews. 2014;19:293-296.
6. Morteale KJ, Ros PR. Benign liver neoplasms. Clin Liver Dis. 2002;6:119-145.
7. Chan JH, Tsui EY, Luk SH, Fung AS, Yuen MK, Szeto ML, et al. Diffusion-weighted MR imaging of the liver: distinguishing hepatic abscess from cystic or necrotic tumor. Abdom Imaging. 2001;26:161-165.

Case Report

8. Lewin M, Mourra N, Honigman I, Fléjou J, Parc R, Arrivé L, et al. Assessment of MRI and MRCP in diagnosis of biliary cystadenoma and cystadenocarcinoma. *Eur Radiol.* 2006;16:407-413.
9. Shiono S, Suda K, Nobukawa B, Arakawa A, Yamasaki S, Sasahara N, et al. Pancreatic, hepatic, splenic, and mesenteric mucinous cystic neoplasms (MCN) are lumped together as extra ovarian MCN. *Pathol Int.* 2006;56:71-77.
10. Lim JH, Zen Y, Jang KT, Kim YK, Nakanuma Y. Cyst-forming intraductal papillary neoplasm of the bile ducts: description of imaging and pathologic aspects. *AJR Am J Roentgenol.* 2011;197:1111-1120.
11. Li T, Ji Y, Zhi XT, Wang L, Yang XR, Shi GM, et al. A comparison of hepatic mucinous cystic neoplasms with biliary intraductal papillary neoplasms. *Clin Gastroenterol Hepatol.* 2009;7:586-593.
12. Zen Y, Jang KT, Ahn S, Kim DH, Choi DW, Choi SH, et al. Intraductal papillary neoplasms and mucinous cystic neoplasms of the hepatobiliary system: demographic differences between Asian and Western populations, and comparison with pancreatic counterparts. *Histopathology.* 2014;65:164-173.
13. Erdogan D, Kloek J, Lamers WH, Offerhaus GJ, Busch OR, Gouma DJ, et al. Mucinous cystadenomas in liver: management and origin. *Dig Surg.* 2010;27:19-23.
14. Zamboni G, Scarpa A, Bogina G, Iacono C, Bassi C, Talamini G, et al. Mucinous cystic tumors of the pancreas: clinicopathological features, prognosis, and relationship to other mucinous cystic tumours. *Am J Surg Pathol.* 1999;23:410-422.
15. Yu Q, Chen T, Wan YL, Min J, Cheng Y, Guo H. Intrahepatic biliary cystadenocarcinoma: clinical analysis of 4 cases. *Hepatobiliary Pancreat Dis Int.* 2009;8:71-74.
16. Delis SG, Touloumis Z, Bakoyiannis A, Tassopoulos N, Paraskeva K, Athanassiou K, et al. Intrahepatic biliary cystadenoma: a need for radical resection. *Eur J Gastroenterol Hepatol.* 2008;20:10-14.
17. Vogt DP, Henderson JM, Chmielewski E. Cystadenoma and cystadenocarcinoma of the liver: a single center experience. *J Am Coll Surg.* 2005;200:727-733.
18. Hytiroglou P, Zurac S, Popescu I, Popovici D, Tanasescu C, Saxena R et al. Biliary cystadenocarcinoma with two types of tumour cells. *Virchows Arch.* 2000;437:555-559.
19. Biava MF, Dao A, Fortier B. Laboratory diagnosis of cystic hydatid disease. *World J Surg.* 2001;25:10-14.
20. Devaney K, Goodman ZD, Ishak KG. Hepatobiliary cystadenoma and cystadenocarcinoma. A light microscopic and immunohistochemical study of 70 patients. *Am J Surg Pathol.* 1994;18:1078-1091.
21. Yamamoto T, Fukumoto N, Ichikawa T, Hai S, Ogawa M, Tanaka S, et al. Huge liver abscess radiologically mimicking cystadenocarcinoma. *Osaka City Med J.* 2009;55:53-59.
22. Sanchez H, Gagner M, Rossi RL, Jenkins RL, Lewis WD, Munson JL, et al. Surgical management of nonparasitic cystic liver disease. *Am J Surg.* 1991;161:113-118; discussion 118-119.
23. Zacherl J, Scheuba C, Imhof M, Jakesz R, Függer R. Long-term results after laparoscopic unroofing of solitary symptomatic congenital liver cysts. *Surg Endosc.* 2000;14:59-62.
24. Emre A, Serin KR, Ozden I, Tekant Y, Bilge O, Alper A, et al. Intrahepatic biliary cystic neoplasms: surgical results of 9 patients and literature review. *World J Gastroenterol.* 2011;17:361-365.
25. Lee JH, Lee KG, Park HK, Lee KS. Biliary cystadenoma and cystadenocarcinoma of the liver: 10 cases of a single center experience. *Hepatogastroenterology.* 2009;56:844-849.
26. Gómez-Martin C, Rodríguez A, Malón D, Cortés-Funes H. Biliary cystadenocarcinoma with mesenchymal stroma. *Clin Transl Oncol.* 2010;12:234-237.
27. Zhang M, Yu J, Yan S, Zheng SS. Cystadenocarcinoma of the liver: a case report. *Hepatobiliary Pancreat Dis Int.* 2005;4:464-467.