



# Encapsulated papillary variant of medullary carcinoma of thyroid with extensive cystic change: an extremely rare presentation

Monika Singh, Arvind Ahuja, Seema Rahar, Minakshi Bhardwaj

Department of Pathology, Atal Bihari Vajpayee Institute of Medical Sciences, New Delhi, Delhi, India  
PGIMER, Dr RML Hospital New Delhi, India

## Abstract

Papillary variant of medullary carcinoma of the thyroid is an unusual subtype with many diagnostic challenges. The authors report a case of papillary variant of thyroid medullary carcinoma in a 37-year-old female, who presented with complaints of pain in the thyroid nodule for the latter two months. Contrast enhanced computed tomography (CECT) neck revealed an enlarged and heterogeneously enhancing left lobe of thyroid. This was followed by hemithyroidectomy for suspicion of colloid goitre. Gross examination of the cut surface of the thyroid parenchyma had a sponge like appearance. On histopathology a diagnosis of encapsulated papillary variant of medullary carcinoma thyroid was made with the help of special stains and immunohistochemistry (IHC).

**Keywords:** medullary carcinoma papillary variant, cystic change, thyroid, immunohistochemistry

## Introduction

Papillary variant of medullary carcinoma thyroid (MCT) is a rare variant with very few cases reported in the literature. As medullary carcinoma can be associated with various hereditary syndromes and its metastasis is known for its grave prognosis, it should be diagnosed at the earliest moment. Due to scarcity of data on papillary variant of MCT and as it mimics various other papillary lesions, its accurate diagnosis is challenging for both the radiologist and the histopathologist. After a comprehensive search of the literature we could find only two previously reported cases of papillary variant of MCT with extensive parenchymal cystic degeneration [1,2]. Herein, we report this rare variant of MCT with unusual radiological and gross appearance and highlight the importance of morphology and IHC in its diagnosis.

## Case report

A 37-year-old female, a known case of hypothyroidism on hormonal

treatment presented to the medical OPD with complaints of pain in the thyroid nodule which had gradually increased in size over the last two months. Past clinical history of the patient revealed that an ultrasonography study of the neck, performed two years back, the left lobe had been completely replaced by a large heterogenous mass measuring 7.8x3.2x8.2 cm with cystic changes, increased vascularity and few calcific foci. Following this, a fine needle aspiration (FNA) of the thyroid nodule was done. FNAC smears showed a few clusters of follicular epithelial cells in a background of abundant colloid and cystic macrophages; the features were suggestive of colloid goiter with cystic degeneration. Since then the patient had been on follow up and had been monitored through repeated thyroid hormone profile which was within normal limits (T3 - 1.15 ng/ml, T4 - 7.60 µg/dl and TSH - 4.65 uIU/ml) with thyroid hormone 25 µg supplement. For the last two months there had been an increase in the size of the mass associated

DOI: 10.15386/mpr-1570

Manuscript received: 10.01.2020

Received in revised form: 03.06.2020

Accepted: 30.06.2020

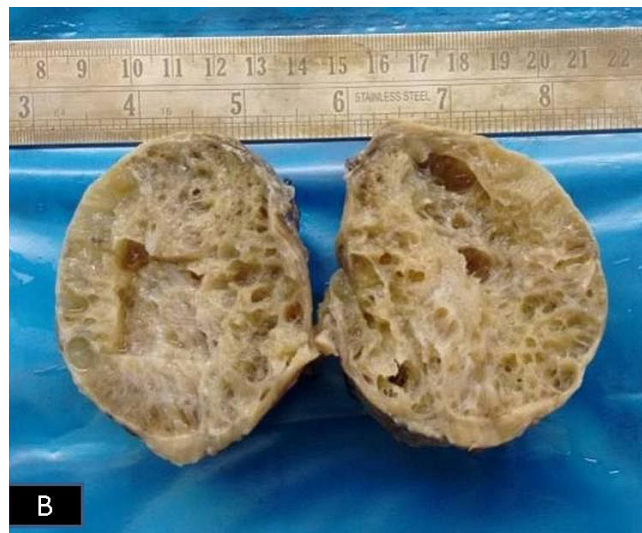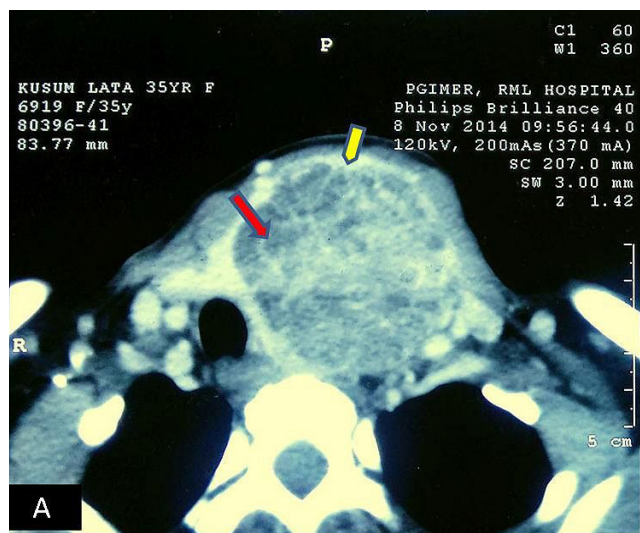
Address for correspondence:  
drarvindahuja@gmail.com

This work is licensed under a Creative Commons Attribution-NonCommercial-NoDerivatives 4.0 International License

with pain. There was no history of weight loss, change of voice or dyspnoea. Computerized tomography (CT) scan of neck was done which revealed a bulky enlarged left lobe of the thyroid gland measuring approximately 7x6x5cm in size displaying a heterogeneous post contrast enhancement with innumerable parenchymal cystic spaces (Figure 1a). Fat planes with adjacent structures such as neck muscles and vessels appeared to be preserved. Few subcentrimetric mildly enhancing lymph nodes were seen at level II on the left side. Right lobe and isthmus appeared unremarkable. Following this a left hemithyroidectomy was performed and the specimen was sent for histopathological examination. Grossly an encapsulated left hemithyroidectomy specimen was received measuring 8x6x4 cm. External surface showed a few hemorrhagic foci otherwise unremarkable. On the cut section, the whole of the thyroid parenchyma was replaced by numerous cysts ranging in size from 0.2 to 2 cm in diameter giving a sponge like appearance (Figure 1b). No residual thyroid parenchyma was identified. Microscopic examination of the sections revealed replacement of most of the parenchyma by varying sized cystic spaces lined by tumour cells with small foci of adjoining preserved parenchyma at the periphery showing features of lymphocytic thyroiditis (Figure 2a). Few of the cysts exhibited micropapillae lined by the tumour cells. However, the nuclear features of the papillary carcinoma were missing in the papillae (Figure 2b, c and d). The intervening interstitial tissue showed acellular pale eosinophilic deposition of amyloid which was congophilic with congo red stain and gave green birefringence on

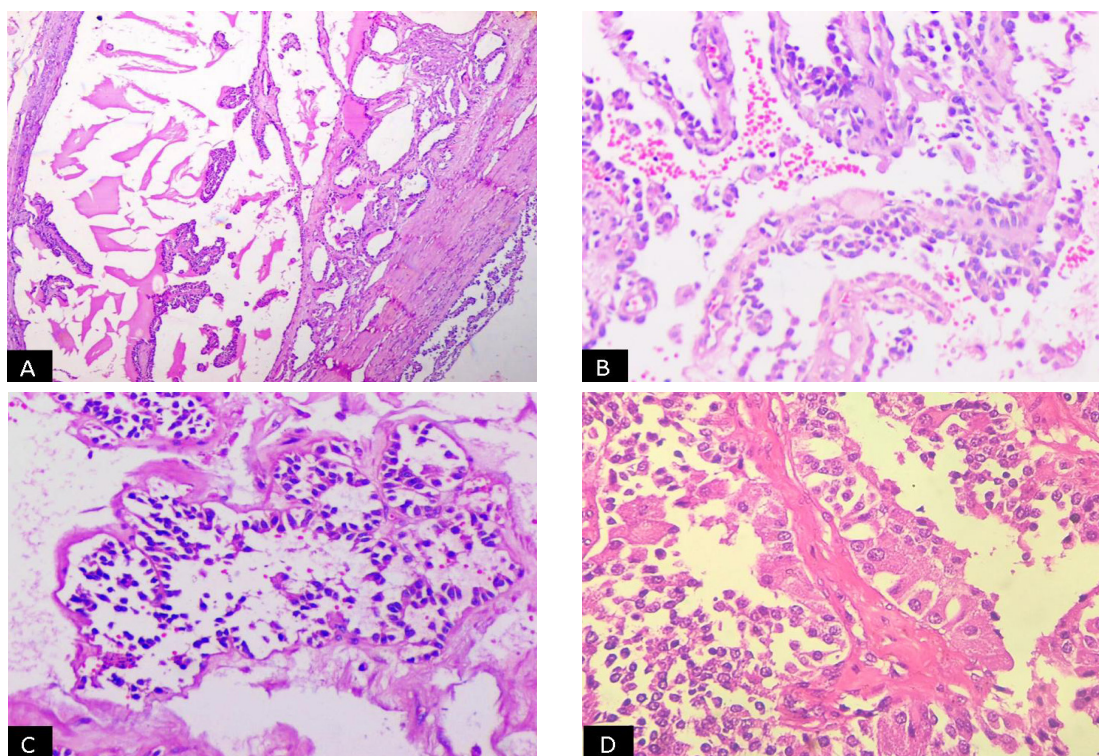
polarization (Figure 3a and b). These findings raised the suspicion of medullary carcinoma thyroid. Accordingly IHC for calcitonin and chromogranin was performed which turned out to be positive in tumour cells. The amyloid deposit also showed calcitonin positivity (Figure 3c and d). Based on the histological and IHC findings, diagnosis of encapsulated papillary variant of medullary carcinoma thyroid was rendered and serum calcitonin was advised. Serum calcitonin was found to be markedly elevated (4805.00 pg/ml). Subsequently the work up for multiple endocrine neoplasia syndrome type 2 (MEN type 2) was planned. This included follow up CT neck, CT abdomen and pelvis and urine vanillylmandelic acid (VMA) levels. No MEN type 2 associated lesions were found in the patient. Following this a completion, thyroidectomy along with left side modified radical neck dissection which included level I to VI cervical lymph nodes was performed in view of the histopathological diagnosis and CT finding of a few enlarged left level II lymph nodes. Grossly the right lobe of the thyroid measured 5.5x2.5x1 cm with unremarkable external surface and cut sections. Histopathology revealed features of Hashimoto thyroiditis. Two of the eleven lymph nodes resected revealed metastasis from the medullary carcinoma of thyroid.

On follow up after 3 weeks of the second surgery, the serum calcitonin level fell to 130 pg/ml. Ultrasonography done at the same time did not reveal any residual disease or recurrence. The patient was advised to follow up after 3 months with a serum calcitonin report; however, the patient did not turn up and was lost to follow up.

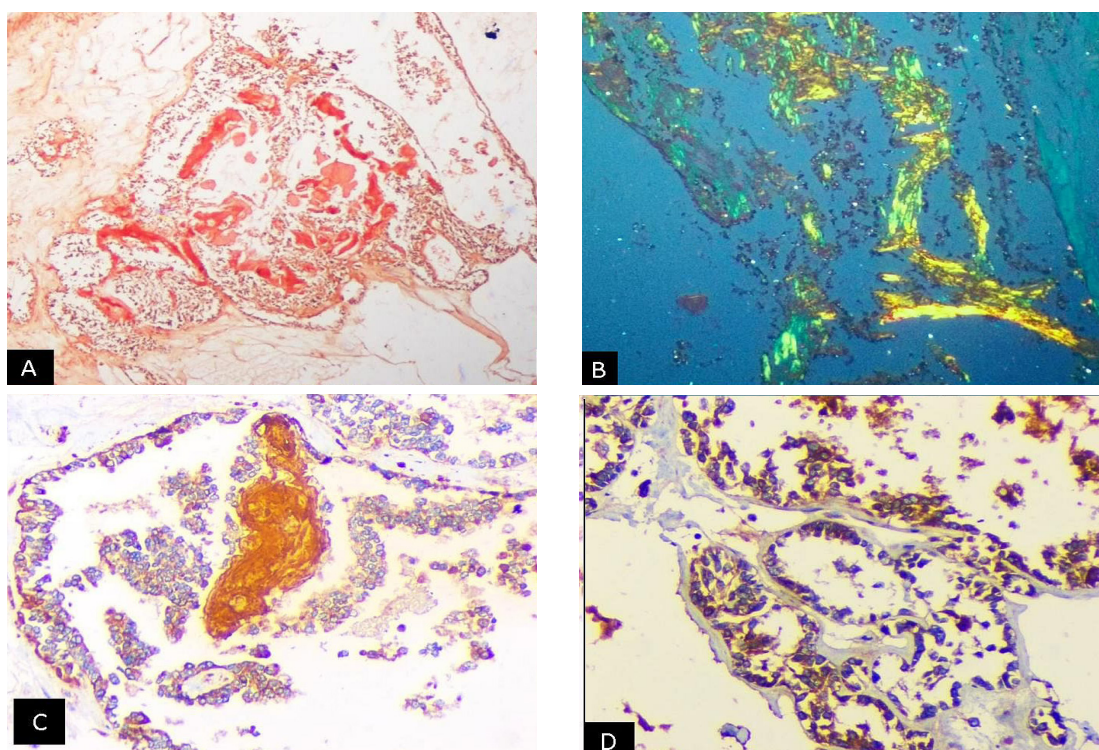


**Figure 1. (A)** Left lobe of thyroid is enlarged and shows heterogeneous post contrast enhancement. It is completely replaced by innumerable hypodense cystic spaces (yellow arrowhead) with intervening enhancing septae (red arrow). **(B)** Gross of left hemithyroidectomy specimen showing the replacement of normal parenchyma by numerous cysts of varying diameters giving a sponge like appearance.





**Figure 2.** Photomicrographs of the histological appearance of the tumour. (A) Varying sized cysts replacing the normal thyroid parenchyma (H&E, 40x); (B,C) Tumor cells in papillary configuration and lining the cystic spaces (H&E, 100x); (D) Tumour cells lacking nuclear clearing or pseudo inclusions (H&E, 400x).



**Figure 3.** (A) Photomicrograph shows amyloid deposition in the interstitial space of the tumor on congo red staining (CR, 100x); (B) Green birefringence under polarized light (CR, 100x); (C) Calcitonin expression was seen in tumor cells as well as in interstitial amyloid deposits (IHC, 200x); (D) Chromogranin immunoreactivity by tumor cells (IHC, 200x).

## Discussion

Medullary carcinoma thyroid is a neuroendocrine tumour arising from the parafollicular cells, mainly secreting calcitonin along with numerous other peptides [3]. It was first described by Hazard et al. in 1959 [4]. Since then there are numerous articles in the English literature detailing their morphological variants and molecular biology.

The majority of MCT are sporadic and differ from hereditary MCT by being mostly unilateral with a later onset of malignancy and absence of associated C cell hyperplasia in most of the cases [5]. WHO classification has enumerated 12 histological variants of MTC apart from the mixed follicular/papillary variants [6]. Medullary carcinoma thyroid has a varied histological pattern mimicking other histologic types. Hence a panel of IHC markers comprising of calcitonin, chromogranin and thyroglobulin is crucial for making an accurate diagnosis [7]. The papillary or pseudopapillary type of MCT is a very rare variant first reported by Kakudo et al. in 1979 [8]. It is characterized by the presence of true or artefactual papillae created by tissue fragmentation and can be differentiated from papillary carcinoma thyroid by their nuclear features and IHC profile [9]. After thoroughly reviewing the literature we could find only two cases of papillary variant of MCT with extensive cystic parenchyma reported by Ozkara et al. in 2002 and Hycza et al. in 2015, as seen in our case [1,2]. Making a correct diagnosis of this variant with an extensive cystic parenchyma is extremely challenging as they mimic other benign/malignant cystic lesions on radiology, as happened in our case. A variety of thyroid lesions show a papillary pattern of arrangement of cells. The main differentials of papillary lesions in a case such as ours are papillary carcinoma, nodular goitre with cystic change, follicular adenoma with papillary hyperplasia, medullary carcinoma papillary variant, columnar cell carcinoma and thyroiditis. Cytological features, architectural pattern, IHC and serological studies should be considered together in such a case.

The papillae in papillary carcinoma have an arborizing pattern and are lined by cells displaying nuclear crowding and characteristic nuclear features which are rarely seen in other lesions. Nodular goitre and follicular adenoma with papillary hyperplasia usually have short papillae lined by columnar cells with regular, basally located noncrowded pattern of nucleus. These papillae often contain follicles in their core. The papillae seen in thyroiditis are usually short, lack a well defined fibrovascular core and usually project into the follicular lumen. Papillae seen in MCT are mostly pseudopapillae and are commonly formed by tissue fragmentation [10].

Amongst the prognostic factors, the age and stage of the disease are the most important based on multivariate analysis. Stage is the most important prognostic factor with survival rates for stage I, II, III and IV being 100%,

80%, 74%, and 25% respectively. Patients older than 45 years have a poorer prognosis [11]. Small sized tumours which are discovered incidentally on routine screening are associated with a good prognosis. Rieu et al. have advocated routine screening of serum calcitonin levels in nodular thyroid lesions for early diagnosis of unsuspected sporadic MCT like our case [12].

Microscopic features such as a high mitotic count ( $>1/25$  high power field), small cell variant, necrosis and squamous metaplasia are associated with a poor prognosis. MCT which are calcitonin poor ( $<50\%$  tumour cells are positive) and also those with absence of amyloid have a worse prognosis. In the present case none of the above mentioned features was noted and the tumour was calcitonin rich with an abundance of amyloid. Tumours with distant metastasis are associated with a grave prognosis. The common sites for distant metastasis are lung, liver, adrenal and bone.

Total thyroidectomy remains the mainstay therapy with limited response to chemotherapy. Targeted therapy has been tried with newer drugs such as vandetanib which is an inhibitor of RET kinase, vascular endothelial growth factor receptor and epidermal growth factor receptor. Such drugs can be used in cases with locally advanced disease or distant metastasis [13].

Our case highlights that medullary carcinoma may show multiple cysts on gross appearance and micropapillae on microscopy. However, identification of amyloid and a panel of IHC can be helpful to reach the definitive diagnosis only when MCT is suspected. This case further widens the differential diagnosis of multicystic thyroid lesions.

## References

1. Ozkara SK, Gürbüz Y, Muezzinoğlu B, Yumbal Z. Encapsulated cystic papillary variant of medullary carcinoma of thyroid gland. *Endocr Pathol.* 2002;13:167-171.
2. Hycza MD, Winer D, Mete O. Images in endocrine pathology: papillary variant of medullary thyroid carcinoma with cystic change. *Endocr Pathol.* 2015;26:87-89.
3. Williams ED. Histogenesis of medullary carcinoma of the thyroid. *J Clin Pathol.* 1966;19:114-118.
4. Hazard JB, Hawk WA, Crile G Jr. Medullary (solid) carcinoma of the thyroid; a clinicopathologic entity. *J Clin Endocrinol Metab.* 1959;19:152-161.
5. Rosenberg-Bourgin M, Gardet P, de Sahb R, Schlumberger M, Caillou B, Guilloud-Bataille M, et al. Comparison of sporadic and hereditary forms of medullary thyroid carcinoma. *Henry Ford Hosp Med J.* 1989;37:141-143.
6. Lloyd RV, Osamura RY, Klöppel G, Rosai J (Eds): *World Health Organisation Classification of Tumours. Pathology and Genetics of Tumours of Endocrine Organs.* IARC Press, Lyon. 2017;110-113.
7. Krisch K, Krisch I, Horvat G, Neuhold N, Ulrich W. The value of immunohistochemistry in medullary

- thyroid carcinoma: a systematic study of 30 cases. *Histopathology*.1985;9:1077-1089.
8. Kakudo K, Miyauchi A, Takai S, Katayama S, Kuma K, Kitamura H. C cell carcinoma of the thyroid--papillary type. *Acta Pathol Jpn*. 1979;29:653-659.
  9. Shukla S, Awasthi NP, Husain N. Papillary variant of medullary carcinoma thyroid. *Indian J Pathol Microbiol*. 2014;57:151-152.
  10. Rosai J, Carcangiu ML. Pitfalls in the diagnosis of thyroid neoplasms. *Pathol Res Pract*.1987;182:169-179.
  11. Pelizzo MR, Boschin IM, Bernante P, Toniato A, Piotto A, Pagetta C, et al. Natural history, diagnosis, treatment and outcome of medullary thyroid cancer: 37 years experience on 157 patients. *Eur J Surg Oncol*. 2007;33:493-497.
  12. Rieu M, Lame MC, Richard A, Lissak B, Sambort B, Vuong-Ngoc P, et al. Prevalence of sporadic medullary thyroid carcinoma: the importance of routine measurement of serum calcitonin in the diagnostic evaluation of thyroid nodules. *Clin Endocrinol (Oxf)*. 1995;42:453-460.
  13. Priya SR, Dravid CS, Digumarti R, Dandekar M. Targeted Therapy for Medullary Thyroid Cancer: A Review. *Front Oncol*. 2017;7:238.