



Airway changes in patients with sleep apnea using AdvanSync2 Class II correctors - a case series

Pasupureddi Keerthana, Gunjan Negi, Prasad Chitra

Department of Orthodontics and
Dentofacial Orthopaedics, Army
College of Dental Sciences,
Secunderabad, India

Abstract

Background. Obstructive sleep apnea (OSA) is a condition that affects a patient's ability to sleep normally, predisposing them to many risks and reduced quality of life. Myofunctional therapy has been proven to increase the airway space according to literature.

Aim. To report the effects of AdvanSync2 Class II corrector in the management of 3 orthodontic patients who reported sleeping difficulties due to breathing problems and retrognathic mandible.

Case presentation. Three patients reported to Department of Orthodontics and Dentofacial Orthopaedics with Class II malocclusion associated with sleep apnea requiring treatment. Clinical examination revealed a retrognathic mandible with airway constriction in all subjects. A non-extraction approach using an AdvanSync2 Class II corrector (Ormco Corp, Glendora, Calif) with fixed appliances was considered. Lateral cephalometric records were obtained at three stages: pre-treatment, post functional and prefinishing/post treatment. The airway was divided into 3 parts in the lateral cephalogram: velopharynx, hypopharynx and glossopharynx. The most constricted part of the airway was noted. Pre and post treatment lateral cephalograms were compared to assess the changes in airway dimensions after using AdvanSync2. Significant enhancement in airway dimensions was noted in all three parts (velopharynx, glossopharynx and hypopharynx) in all patients.

Conclusion. Airway assessment is an important aspect in orthodontic diagnosis. Use of the AdvanSync2 Class II corrector in combination with fixed orthodontic appliances enhanced quality of life in Class II patients by improving airway dimensions. This approach can be recommended in the management of mild to moderate Class II malocclusions associated with mandibular retrognathism and airway constriction.

Keywords: airway, AdvanSync 2, Class II corrector, modified Herbst, sleep apnea

Introduction

Obstructive sleep apnea (OSA) is a sleep disorder, characterized by episodes of breathing interruption during sleep. Obstruction of upper airway (OUA) is ensnared with development of OSA [1]. 0.7%-2.9% of children may present with large tonsils and adenoids, a major contributing factor in OUA [2,3].

OSA induces neurobehavioral prodromal symptoms and cardiovascular

disturbances. There have been instances of hyperactive and inattentive activity in children with OSA and habitual snoring [4]. Snoring during sleep is an alarming indicator of a constricted airway which is frequently noted in school children [5]. The ratio of symptomatic daily snoring and obstructive sleep apnea (OSA) is in the range of 3:1 to 5:1. Some of the non-invasive treatment options in OSA are medication, orthodontic procedures

DOI: 10.15386/mpr-1922

Manuscript received: 30.09.2020

Received in revised form: 22.10.2020

Accepted: 12.11.2020

Address for correspondence:
prasadchitra@yahoo.co.uk

This work is licensed under a Creative
Commons Attribution-NonCommercial-
NoDerivatives 4.0 International License

including maxillary expansion, functional therapy and positive airway reinforcement. Children with respiratory disorders during growth may show impaired development of maxillofacial structures and vice versa [6].

Therefore, detailed assessment of the upper airway is essential, in patients presenting with a skeletal deformity, as an irregular maxillofacial form can be influenced by respiratory function. Such cases in children can be referred to orthodontists, as in many instances, improvement can be achieved with orthodontic procedures. Although, the “gold standard” for diagnosis is polysomnography [2], limited resources in developing countries act as obstacles to proper diagnosis and management of OSA. Thus, cephalometric images which are usually utilized during orthodontic treatment were evaluated in this study.

The management of three patients who presented with a chief complaint of snoring and dyspnea are discussed in this case series. On clinical examination, a constricted airway with retrognathic mandible was noted in all subjects. A combination approach utilizing fixed Class II correctors in conjunction with fixed orthodontic appliances was used to manage the Class II malocclusion. Previous studies in literature have shown improvement in pharyngeal airway

dimensions using myofunctional therapy [7-9]. However, the effects of a recently introduced Class II corrector; AdvanSync2 has not yet been evaluated. The advantage of using this fixed functional appliance is that Class II correction can be carried out from the start of treatment helping to reduce treatment time and patient discomfort.

Therefore, the aim of the study was to evaluate the airway dimensional changes in patients with Class II malocclusion associated with mandibular retrusion and OSA amenable to treatment with the Advansync2 Class II corrector.

Case report 1

A 14-year-old post pubertal female was referred by an ENT surgeon for orthodontic evaluation of her dentition, mouth-breathing and snoring. She gave a history of daytime sleepiness and difficulty in concentrating in school for extended time periods. Clinical investigation showed a convex profile with a retrusive mandible, an obtuse nasolabial angle, full permanent dentition with a bilateral Class II molar relationship, 9 mm overjet and 6.5 mm overbite (Figure 1). Her VTO (visual treatment objective) was positive in evaluating suitability for a functional appliance.

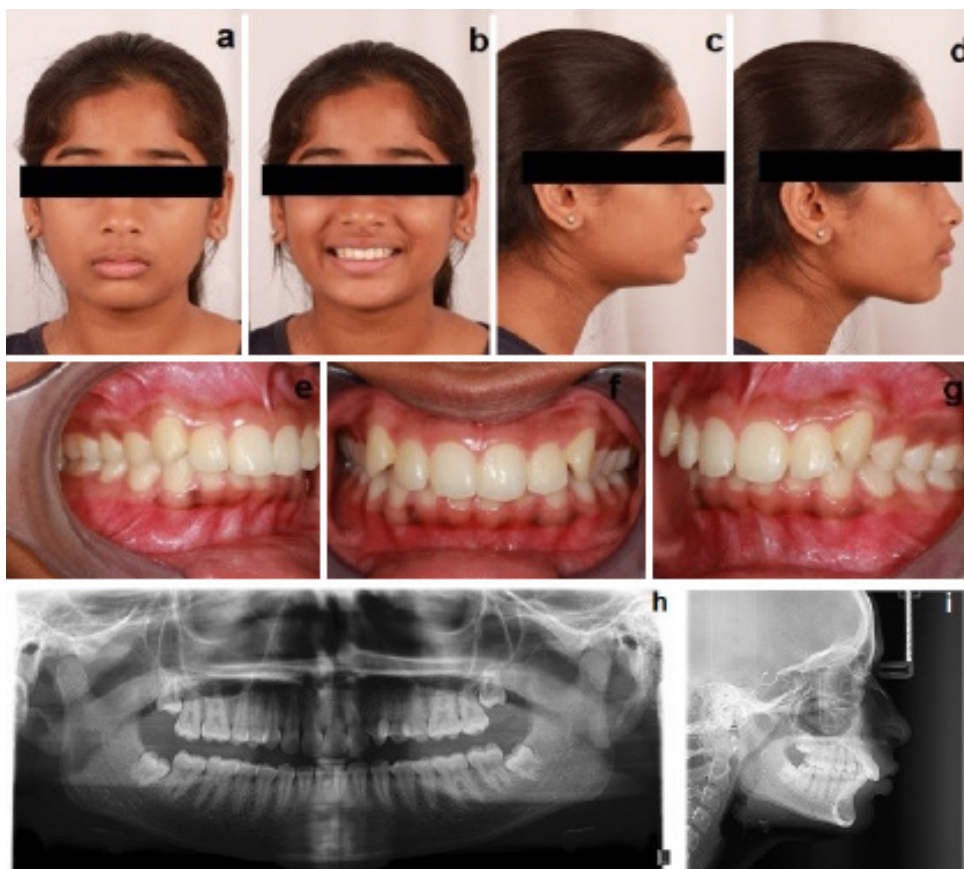


Figure 1. Pre-treatment: (a-d) Extraoral; (e-g) Intraoral photographs; (h,i) Radiographs.

Radiographic examination confirmed a skeletal Class II division 1 malocclusion due to a retrognathic mandible with SNB reduced to 77°, ANB of 5°, hypo divergent growth pattern (FMA = 21°), proclined mandibular incisors (IMPA = 109°) and reduced lower anterior facial height of 51 mm. Cephalometric findings indicated severe airway constriction (velopharynx- 4.5 mm, glossopharynx -8.2mm, and hypopharynx- 9.3 mm) (Table I and Figure 2a).

Airway measurement was performed using a previously published method [10,11]. Three planes subdivided the pharyngeal airway into velopharynx, glossopharynx and hypopharynx: P1 [hard palate to soft palate caudal margin (CmSp)], P2 [CmSp to epiglottis base] and P3 [base of tongue to larynx]. Linear distances were measured at the most constricted point in all 3 parts of airway using Nemotec Dental Studio1.0. Software (Nemotec SL, Madrid, Spain).

Table I. Pre and Post treatment cephalometric data.

Variable	Pre-treatment	Post-treatment
SNA	82°	81°
SNB	77°	79°
ANB	5°	2°
FMA	21°	25°
IMPA	109°	111°
LAFH	51 mm	55 mm
Nasolabial angle	119°	118°
Skeletal convexity	4 mm	2 mm
Velopharynx width	4.5 mm	9.1 mm
Glossopharynx width	8.2 mm	10.5 mm
Hypopharynx width	9.3 mm	11.1 mm

* SNA, Sella-Nasion-Subspinale Angle; SNB, Sella-Nasion-Supramentale Angle; ANB, Subspinale-Nasion-Supramentale Angle; FMA, Frankfort Mandibular Plane Angle; IMPA, Incisor Mandibular Plane Angle; LAFH, Lower anterior facial height.

The major treatment objective was to relocate the retrognathic mandible anteriorly to a Class I relation in order to obtain ideal occlusion and increase pharyngeal airway space. A non-extraction approach utilizing a fixed Class II corrector (Advansync2,Ormco Corp, Glendora, Calif) in conjunction with self ligating Damon fixed appliances (Damon 3MX,Ormco Corp, Glendora, Calif) was used (Figure 3). Initial 0.013" Copper-Nickel-Titanium (CuNiTi) archwires were placed in both arches for leveling, aligning and beginning lateral arch development. The fixed Class II corrector was also placed at this time. These archwires were replaced after 10 weeks with 0.018" CuNiTi wires. 14 x 25" rectangular CuNiTi archwires replaced 0.018" CuNiTi wires after 12 weeks. The Class II corrector was reactivated thrice over 6 months using 2 mm spacers. The overjet reduced from 9 mm to 2 mm in nine months. Cephalometric analysis revealed an improved ANB angle of 2°, FMA at 25°, and slight increase in lower anterior facial height at 55 mm with reduced skeletal convexity of 2 mm. The Class II corrector helped reposition the mandible and improved upper airway dimensions. There was improvement in all assessed pharyngeal airway dimensions. More significantly, the velopharyngeal airway dimensions improved from 4.5 mm to 9.1 mm (Figure 2b,2c).

A Class I skeletal and dental relation was achieved using the Class II corrector. The Class II corrector was then removed, second molars tubes were bonded, 18 × 25" CuNiTi archwires were placed for 8 weeks followed by stainless steel 19 x 25" final wires for an additional 10 weeks (Similar wire sequencing was utilized for all patients). Settling elastics were given for a short duration to ensure good interdigitation and occlusion and appliances were debonded (Figure 4).

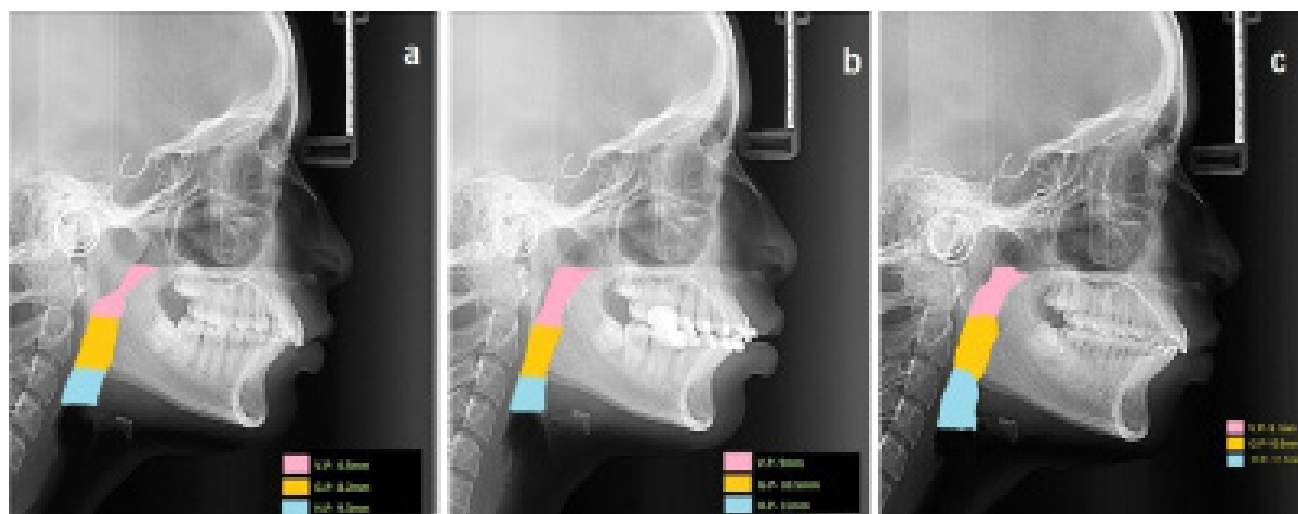


Figure 2. Airway assessment: (a) Pretreatment; (b) Post functional; (c) Post treatment.

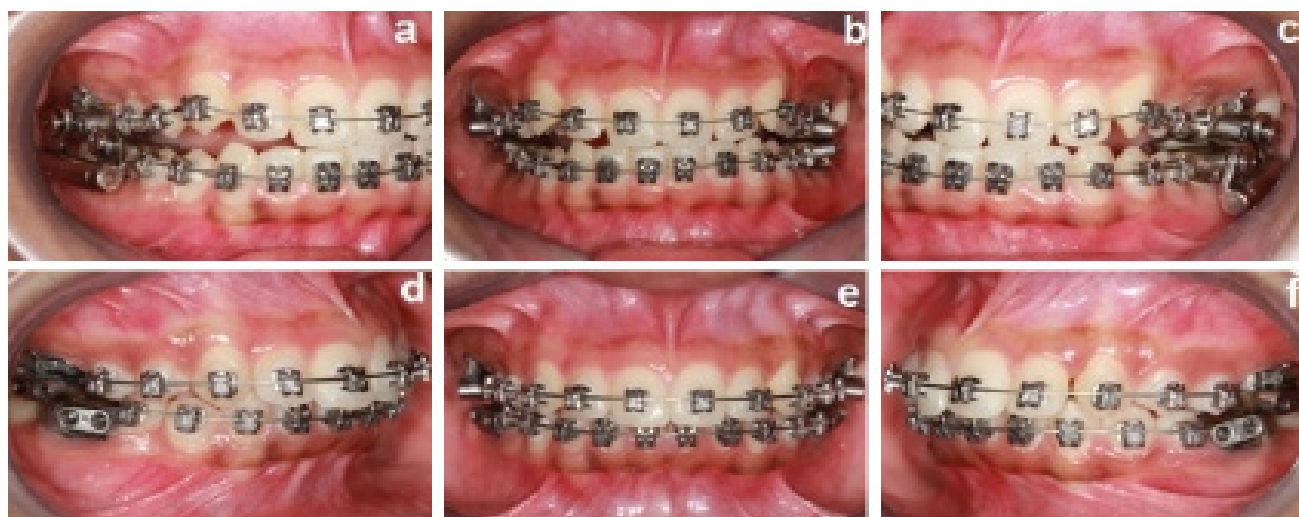


Figure 3. (a-c) Bonding of Damon 3MX brackets with simultaneous placement of AdvanSync2; (d-f) Post functional intra oral photographs.

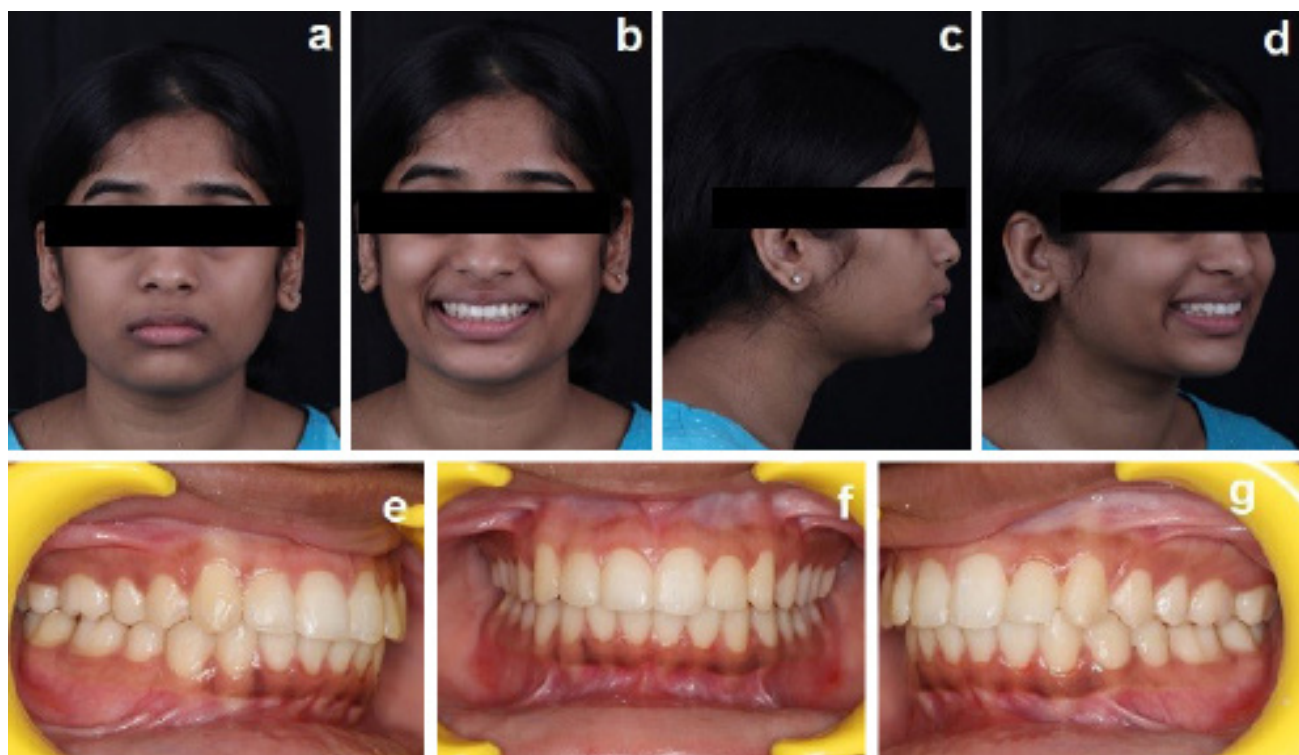


Figure 4. Post treatment: (a-d) Extraoral; (e-g) Intraoral photographs.

Duration of treatment was significantly shortened since a majority of tooth movement was completed during the functional phase. Upper wrap around removable and lower fixed canine to canine retainers were given. Overall treatment time was 14 months. The patient reported significant improvement in sleep related symptoms with improved grades in school on 6 months review.

Case report 2

A 13-year-old male patient complained of forwardly placed upper front teeth and difficulty in breathing while playing sports. Examination revealed a convex profile, acute nasolabial angle, Class II molar relation bilaterally, increased overjet of 8mm and overbite of 6 mm (Figure 5a-f).

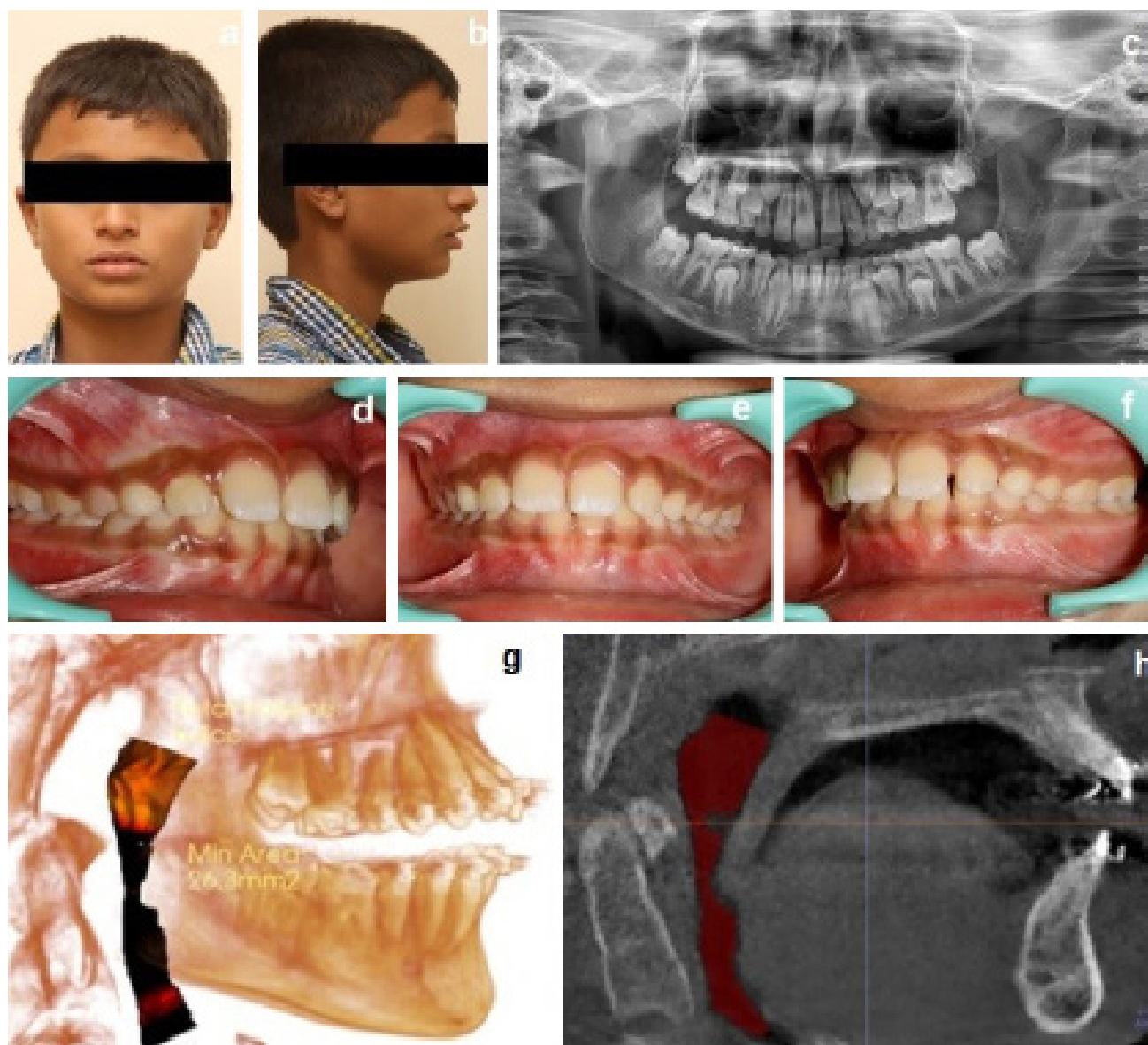


Figure 5. Pre-treatment: (a,b) Extraoral; (c) OPG; (d-f) Intraoral photographs; (g,h) Pre-treatment airway assessment on CBCT.

Cephalometric analysis showed skeletal convexity of 4mm, retrognathic mandible with SNB at 72°, ANB increased to 6°, FMA at 24°, lower anterior facial height of 50 mm, IMPA of 106° (Table II) and severe airway constriction (Figure 5g, 5h). VTO was positive.

Treatment involved use of non-extraction mechanics in conjunction with a Class II corrector and fixed orthodontic appliances. The Class II corrector was placed initially for 5 months which enabled mandibular relocation into Class I with improvement in dental relations and airway dimensions. Self ligating fixed orthodontic appliances (Damon Q) were placed for dental corrections (Figure 6a-f).

Table II. Pre and Post treatment cephalometric data.

Variable	Pre-treatment	Post-treatment
SNA	78°	77°
SNB	72°	75°
ANB	6°	2°
FMA	24°	25°
IMPA	106°	109°
LAFH	50 mm	53 mm
Nasolabial angle	87°	89°
Skeletal convexity	4 mm	2 mm
Velopharynx width	7 mm	9.5 mm
Glossopharynx width	6 mm	7.7 mm
Hypopharynx width	8.3 mm	8.5 mm

* SNA, Sella-Nasion-Subspinale Angle; SNB, Sella-Nasion-Supramentale Angle; ANB, Subspinale-Nasion-Supramentale Angle; FMA, Frankfort Mandibular Plane Angle; IMPA, Incisor Mandibular Plane Angle; LAFH, Lower anterior facial height

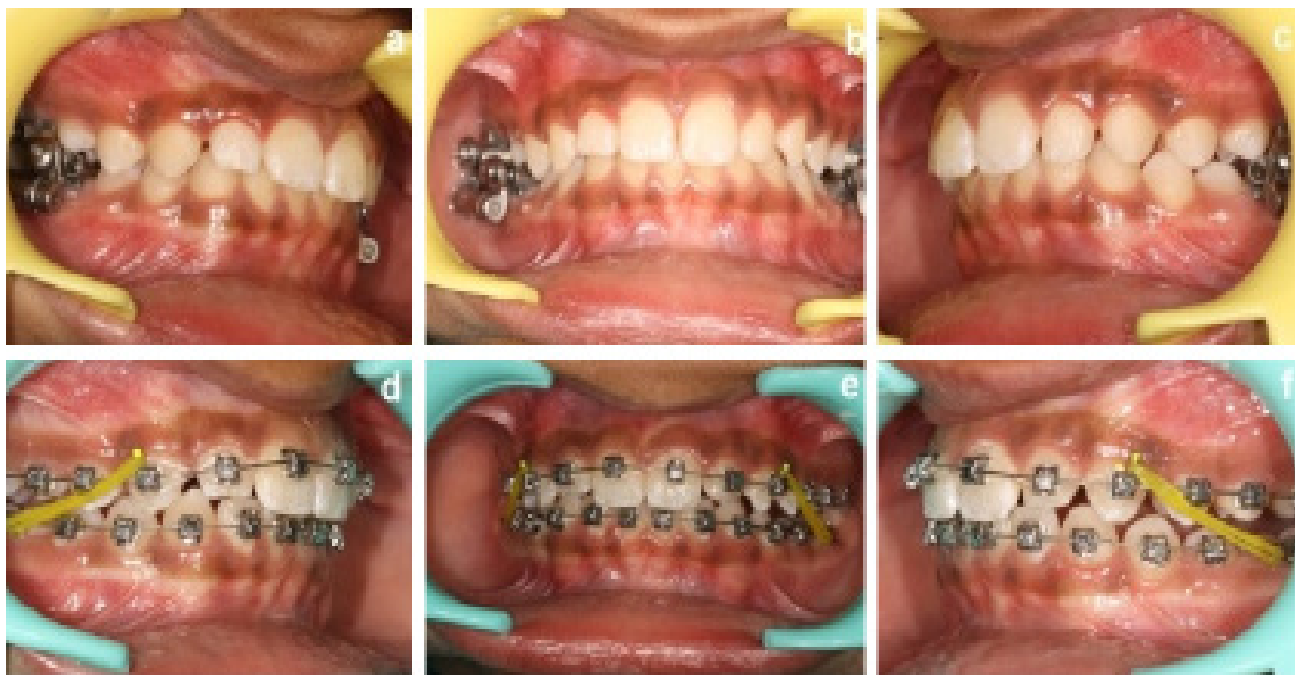

Figure 6. (a-c) Advansync2 placement; (d-f) Post functional bonding of Damon Q brackets.

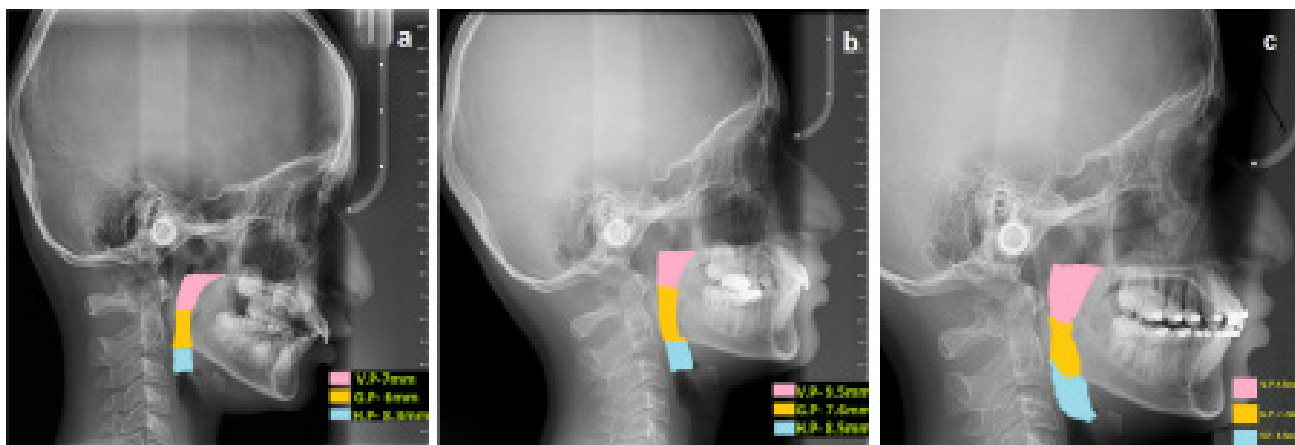


Figure 7. Airway assessment: (a) Pretreatment; (b) Post functional; (c) Pre finishing.

Post-functional cephalometric analysis showed a significant increase in airway dimensions and improved ANB angle of 2° (Figure 7). Fixed appliance therapy was continued for an additional 10 months to fine-tune occlusion after which the appliances were debonded and retainers given (Figure 8). Overall treatment duration was 15 months. The patient was pleased with his facial appearance and could breathe more comfortably without exertion while playing sports.

Case report 3

A 14-year post pubertal female reported with a complaint of protrusive upper front teeth and snoring during sleep. She had undergone orthodontic treatment with extractions of 1st premolars previously. She had a convex profile, an acute nasolabial angle, bilateral Class II molar relation with an overjet of 9 mm and overbite of 5 mm (Figure 9).

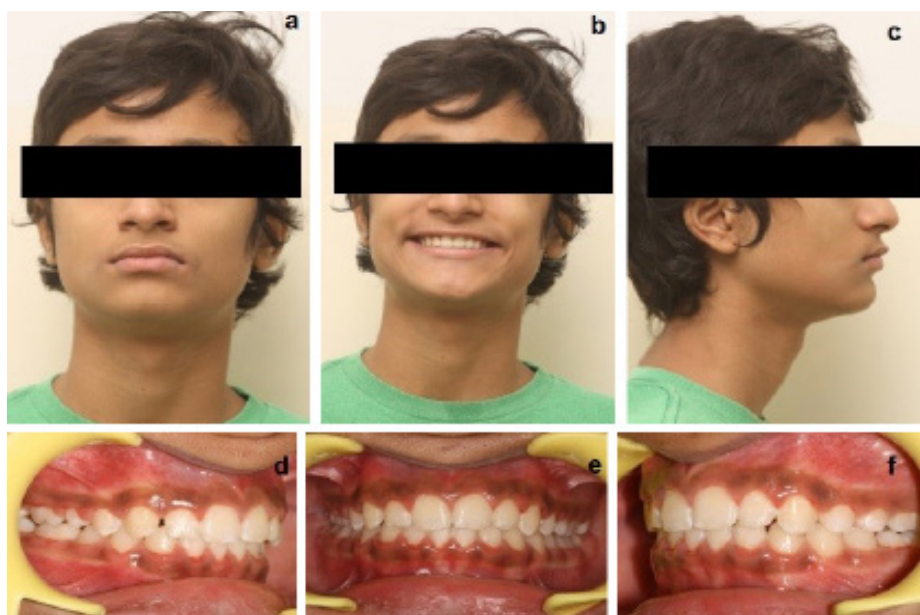

Figure 8. Post treatment: (a-c) Extraoral; (d-f) Intraoral photographs.

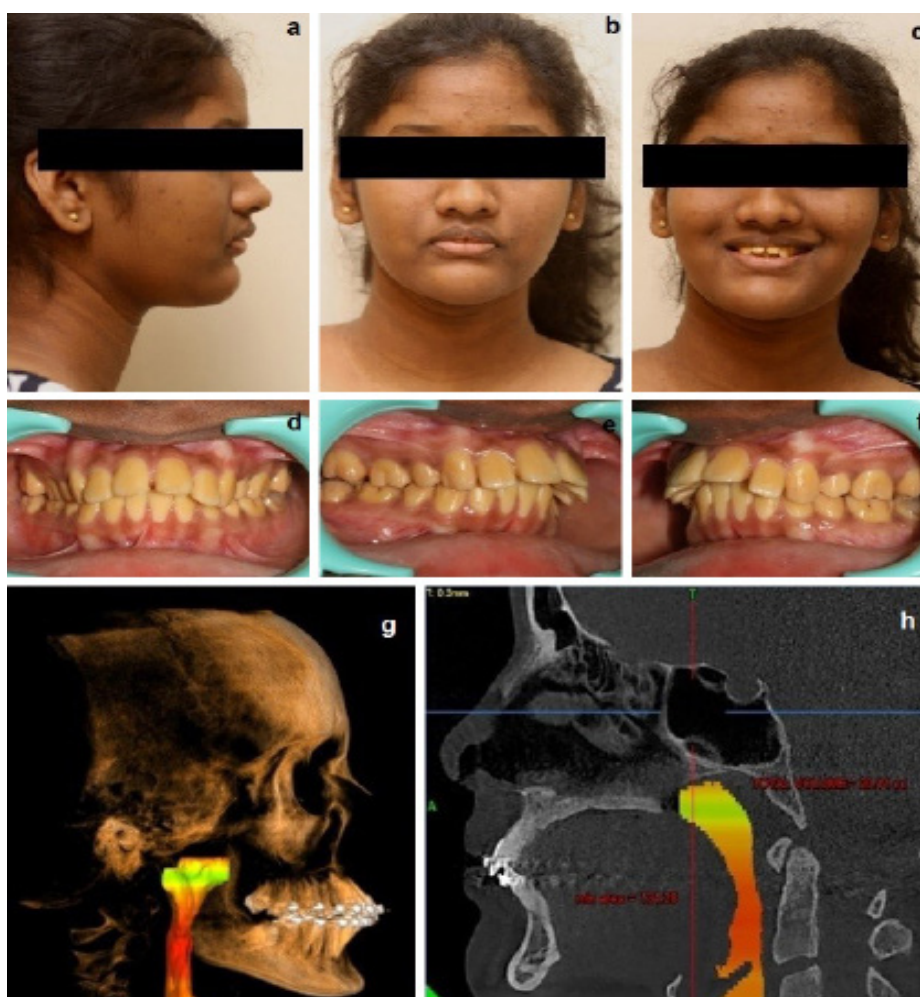


Figure 9. Pre-treatment: (a-c) Extraoral; (d-f) Intraoral photographs; (g, h) Pre-treatment airway assessment on CBCT.

Case Report

She had a retrusive mandible and a positive VTO. Radiographic analysis revealed a Class II skeleton and dentition with average airway dimensions (Table III). A Class II corrector was placed simultaneously with Damon 3MX self ligating brackets for skeletal and dental corrections (Figure 10a-10c).

The Class II corrector was activated twice using spacers over a period of 6 months to obtain an overjet of 2mm. A Class I molar relation with ideal overjet and overbite was achieved (Figure 10d-10f). Post-functional cephalometric changes showed an improved ANB of 1°, FMA at 26°, IMPA at 106° with improvement in airway dimensions (Figure 11).

There was significant profile improvement. Following functional therapy, the patient reported an improvement in facial appearance and undisturbed sleep. The fixed orthodontic appliances were utilized to refine occlusion and appliances were debonded (Figure 12). Total treatment time was 15 months.

Table III. Pre and post treatment cephalometric data.

Variable	Pre-treatment	Post-treatment
SNA	80°	79°
SNB	76°	78°
ANB	4°	1°
FMA	21°	26°
IMPA	102°	106°
LAFH	49 mm	53 mm
Nasolabial angle	84°	97°
Skeletal convexity	3 mm	1.5 mm
Velopharynx width	7.8 mm	8.4 mm
Glossopharynx width	8.3 mm	9.2 mm
Hypopharynx width	10 mm	11.1 mm

* SNA, Sella-Nasion-Subspinale Angle; SNB, Sella-Nasion-Supramentale Angle; ANB, Subspinale-Nasion-Supramentale Angle; FMA, Frankfort Mandibular Plane Angle; IMPA, Incisor Mandibular Plane Angle; LAFH, Lower anterior facial height

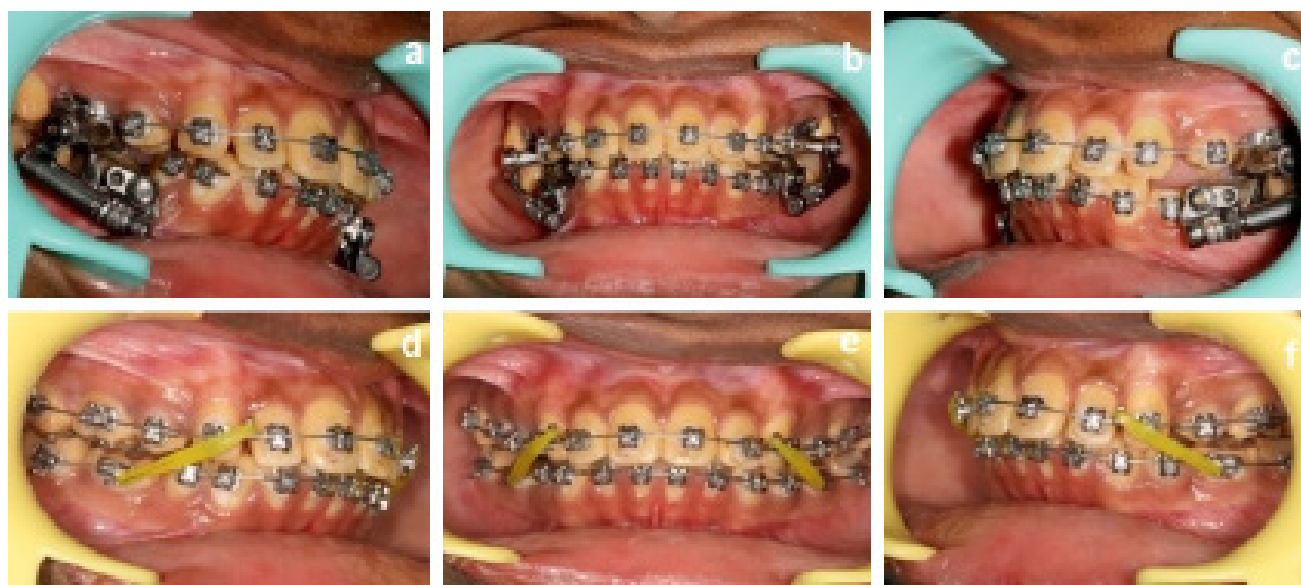

Figure 10. (a-c) Bonding of Damon 3MX brackets with simultaneous placement of AdvanSync2; (d-f) Post functional intra oral photographs.

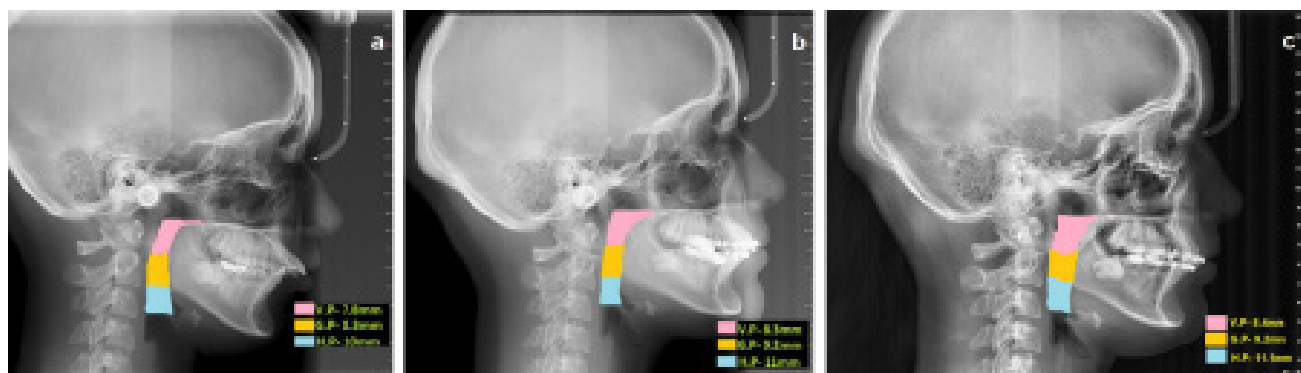


Figure 11. Airway assessment: (a) Pretreatment; (b) Post functional; (c) Pre finishing.

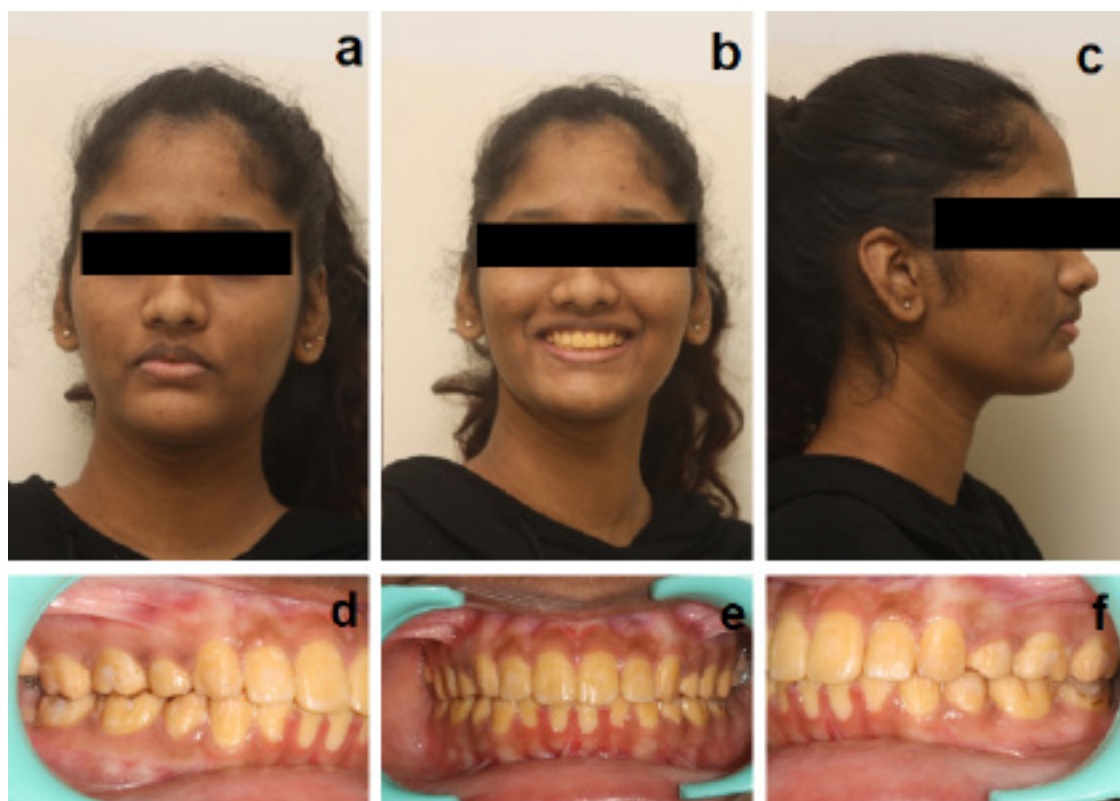

Figure 12. Post treatment: (a-c) Extraoral; (d-f) Intraoral photographs.

Discussion

Since 1975, sleep apneas have been identified as the major cause of rapid infant death syndrome [12]. Risk factors like asthma, cigarette smoke exposure and aberrant craniofacial forms are potential contributing factors for children [13,14], in which malocclusion plays a major role [15]. Upper airway, craniofacial morphology and OSA are closely inter-related [16]. Hence, a pharyngeal structure evaluation on radiographs and/or CBCT scans is a must in such cases.

Functional appliances bring about growth modulation by directing forces towards the mandibular condyle [17]. Additionally, the tongue and hyoid bone are repositioned forward which further helps in increasing the pharyngeal airway space [18]. The importance of constricted upper airway sites in airflow dynamics has been discussed in literature [19].

Since the 1900's, functional appliances have been in use to manage mandibular retrognathism, with fixed functional appliances introduced later to improve patient compliance. Three cases with a Class II div 1 malocclusion and mandibular retrusion were managed conservatively with Class II correctors and fixed orthodontic appliances. There was a significant improvement in all 3 parts of

pharyngeal airway following orthodontic treatment. This is in accordance with previous studies [20-22]. The increase in airway dimensions can be attributed to anterior mandibular and hyoid bone relocation with forward tongue repositioning thus, increasing posterior airway space. This is supported by studies [18,19,23] which have proved that removable and fixed functional appliances increase oropharyngeal airway dimensions in patients.

Few other studies which supported our results were the systematic reviews by Kannan et al. [24] and Sakamoto et al. [25], who found significant increase in pharyngeal airway dimensions with the use of functional appliances.

A likely reason why the AdvanSync2 Class II corrector gave positive results is that it could be used from the start of treatment utilizing residual growth potential without the need for heavy dimension archwires, as required with other fixed functional appliances. IMPA angulation increased 3°-4° post treatment. Proclination of the lower incisors after functional appliance therapy is commonly observed [26]. Additionally, the functional appliance exerted a headgear-like effect (SNA reduced by 1°) and significantly impeded mesial movement of the maxillary molars which was beneficial in obtaining a

Class I relation [27]. At the same time, mesial mandibular molar movement was enabled. SNB also increased post-treatment by 2°-3°.

Lower anterior facial height showed a mild increase which was probably due to extrusion of the maxillary molars. Increase in the lower facial height is beneficial in patients presenting with average to horizontal growth, as in these cases. A systematic review and meta-analysis of the stability of cases treated with fixed functional appliances found that cases treated with the Herbst's appliance were the most stable long-term [28]. As the AdvanSync2 is modelled on the original Herbst's model, stable results could be expected. Another systematic review found that changes in pharyngeal airway dimensions following mandibular advancement were maintained in the long term [7].

In this study, airway dimensional changes were assessed using an established tool in evaluation of the airway, lateral cephalograms [3]. Cone-beam computed tomography (CBCT) has conclusively proven to be an excellent and efficient tool for measuring airway dimensions because it can reliably identify the borders between airway spaces and soft tissues in adult and pediatric patients [7]. A significant mean increase in airway dimensions was noted in the all the 3 parts of the airway, in velopharynx (case 1: 4.5 to 9.1 mm, case 2: 7 to 9.5 mm, case 3 :7.8 mm to 8.4 mm), glossopharynx (case 1: 8.2 to 10.5 mm, case 2: 6 to 7.7 mm, case 3:8.3 mm to 9.2 mm), and hypopharynx (case 1: 9.3 to 11.1 mm, case 2: 8.3 to 8.5 mm, case 3:10 mm to 11.1 mm).

Post pubertal Class II skeletal cases can also be treated with bicuspid extractions. Studies suggest that patients treated with therapeutic orthodontic bicuspid extractions are more prone to airway obstruction due to retraction of incisors into the tongue space [29,30]. Hence, a tailored treatment plan, as per each patient's craniofacial morphology, aesthetics and functional efficiency should be planned. Extraction therapy should be considered only after airway evaluation. In cases requiring detailed examination, CBCT scans should be obtained where airway dimensions can be studied in much greater detail.

Conclusion

Nowadays dentists, particularly pediatric dentists and orthodontists, are at the forefront of successful management of OSA symptoms in children and young adults. Good clinical assessment backed with radiographic evidence can help in diagnosis and treatment planning.

Patients presenting with mild to moderate Class II malocclusions with airway constriction can be managed orthodontically using AdvanSync2 Class II correctors with fixed appliances. This conservative mode of treatment enhances the patients' quality of life by improving airway dimensions.

Clinical implications

- Airway assessment should be an integral part of diagnosis in all orthodontic patients presenting with mandibular retrusion and Class II malocclusion.
- Fixed functional appliances could have supplementary effects such as the improvement in airway dimensions in Class II malocclusions.
- The AdvanSync2 Class II corrector can be successfully used in mild to moderate Class II malocclusions associated with mandibular retrusion and airway constriction.

References

1. Iwasaki T, Saitoh I, Takemoto Y, Inada E, Kanomi R, Hayasaki H, et al. Evaluation of upper airway obstruction in Class II children with fluid-mechanical simulation. *Am J Orthod Dentofacial Orthop.* 2011;139:e135-e145.
2. Rosen CL. Obstructive sleep apnea syndrome in children: controversies in diagnosis and treatment. *Pediatr Clin North Am.* 2004;51:153-167.
3. Major MP, Flores-Mir C, Major PW. Assessment of lateral cephalometric diagnosis of adenoid hypertrophy and posterior upper airway obstruction: a systematic review. *Am J Orthod Dentofacial Orthop.* 2006;130:700-708.
4. Chervin RD, Archbold KH, Dillon JE, Panahi P, Pituch KJ, Dahl RE, et al. Inattention, hyperactivity, and symptoms of sleep-disordered breathing. *Pediatrics.* 2002;109:449-456.
5. Capdevila OS, Kheirandish-Gozal L, Dayyat E, Gozal D. Pediatric obstructive sleep apnea: complications, management, and long-term outcomes. *Proc Am Thorac Soc.* 2008;5:274-282.
6. Iwasaki T, Yamasaki Y. Relation between maxillofacial form and respiratory disorders in children. *Sleep Biol Rhythms.* 2014;12:2-11.
7. Anusuya V, Jena AK, Sharan J. Effects of functional appliance treatment on pharyngeal airway passage dimensions in Class II malocclusion with retrognathic mandibles: A systematic review. *APOS Trends Orthod.* 2019;9:138-148
8. Xiang M, Hu B, Liu Y, Sun J, Song J. Changes in airway dimensions following functional appliances in growing patients with skeletal class II malocclusion: A systematic review and meta-analysis. *Int J Pediatr Otorhinolaryngol.* 2017;97:170-180.
9. Abdalla Y, Brown L, Sonnesen L. Effects of a fixed functional appliance on upper airway volume: A 3-dimensional cone-beam computed tomography study. *Am J Orthod Dentofacial Orthop.* 2020;158:40-49.
10. Schwab RJ. Upper airway imaging. *Clin Chest Med.* 1998;19:33-54.
11. Wen X, Wang X, Qin S, Franchi L, Gu Y. Three-dimensional analysis of upper airway morphology in skeletal Class III patients with and without mandibular asymmetry. *Angle Orthod.* 2017;87:526-533.
12. Jaiswal M, Divya P, Singh S. Obstructive Sleep Apnea in Children and the Role that Dentists Play: A Review. *EC Dental Science.* 2019;18:959-966.

13. Katyal V, Pamula Y, Martin AJ, Daynes CN, Kennedy JD, Sampson WJ. Craniofacial and upper airway morphology in pediatric sleep-disordered breathing: Systematic review and meta-analysis. *Am J Orthod Dentofacial Orthop.* 2013;143:20-30.e3.
14. Flores-Mir C, Korayem M, Heo G, Witmans M, Major MP, Major PW. Craniofacial morphological characteristics in children with obstructive sleep apnea syndrome: a systematic review and meta-analysis. *J Am Dent Assoc.* 2013;144:269-277.
15. Banabilh SM. Orthodontic view in the diagnoses of obstructive sleep apnea. *J Orthod Sci.* 2017;6:81-85.
16. Mislik B, Hänggi MP, Signorelli L, Peltomäki TA, Patcas R. Pharyngeal airway dimensions: a cephalometric, growth-study-based analysis of physiological variations in children aged 6-17. *Eur J Orthod.* 2013;36:331-339.
17. Paulose J, Antony PJ, Sureshkumar B, George SM, Mathew MM, Sebastian J. PowerScope a Class II corrector- A case report. *Contemp Clin Dent.* 2016;7:221225.
18. Bavbek NC, Tuncer BB, Turkoz C, Ulusoy C, Tuncer C. Changes in airway dimensions and hyoid bone position following class II correction with forsus fatigue resistant device. *Clin Oral Investig.* 2016;20:1747-1755.
19. Morrison DL, Launois SH, Isono S, Feroah TR, Whitelaw WA, Remmers JE. Pharyngeal narrowing and closing pressures in patients with obstructive sleep apnea. *Am Rev Respir Dis.* 1993;148:606-611.
20. Ghodke S, Utreja AK, Singh SP, Jena AK. Effects of twin-block appliance on the anatomy of pharyngeal airway passage (PAP) in class II malocclusion subjects. *Prog Orthod.* 2014;15:68.
21. Ruf S, Pancherz H. Dentoskeletal effects and facial profile changes in young adults treated with the Herbst appliance. *Angle Orthod.* 1999;69:239-246.
22. Schweitzer M, Pancherz H. The incisor-lip relationship in Herbst/multibracket appliance treatment of Class II, Division 2 malocclusions. *Angle Orthod.* 2001;71:358-363.
23. Jena AK, Duggal R, Parkash H. Skeletal and dentoalveolar effects of Twin-block and bionator appliances in the treatment of Class II malocclusion: a comparative study. *Am J Orthod Dentofacial Orthop.* 2006;130:594-602.
24. Kannan A, Sathyanarayana HP, Padmanabhan S. Effect of functional appliances on the airway dimensions in patients with skeletal class II malocclusion: A systematic review. *J Orthod Sci.* 2017;6:54-64.
25. Sakamoto Y, Furuhashi A, Komori E, Ishiyama H, Hasebe D, Sato K et al. The Most Effective Amount of Forward Movement for Oral Appliances for Obstructive Sleep Apnea: A Systematic Review. *Int J Environ Res Public Health.* 2019;16:3248.
26. Pancherz H, Anehus-Pancherz M. The headgear effect of the Herbst appliance: a cephalometric long-term study. *Am J Orthod Dentofacial Orthop.* 1993;103:510-520.
27. Al-Jewair TS, Preston CB, Moll EM, Dischinger T. A comparison of the MARA and the AdvanSync functional appliances in the treatment of Class II malocclusion. *Angle Orthod.* 2012;82:907-914.
28. Bock NC, von Bremen J, Ruf S. Stability of Class II fixed functional appliance therapy - a systematic review and meta-analysis. *Eur J Orthod.* 2016;38:129-139.
29. Ng JH, Song YL, Yap AUJ. Effects of bicuspid extractions and incisor retraction on upper airway of Asian Adults and late adolescents: A systematic review. *J Oral Rehabil.* 2019;46:1071-1087.
30. Nasser A, Alshammari R, Al-Jewair T, Aldosari M, Sahar A. Post-orthodontic pharyngeal airway changes following first premolar extraction and incisor retraction in bimaxillary protrusion patients - a retrospective study. *J Res Med Dent Sci.* 2019;7:29-37.