



Combined conservative treatment of a recurrent mandibular keratocyst by enucleation, diode laser, 5-Fluorouracil and dental implants: a case report with 18 years-follow up

Antoine Berberi¹, Georges Aoun², Bouchra Hjeij³, Maissa AboulHosn¹

1) Department of Oral and Maxillofacial Surgery, Faculty of Dental Medicine, Lebanese University, Beirut, Lebanon

2) Department of Oral Medicine and Maxillofacial Radiology, Faculty of Dental Medicine, Lebanese University, Beirut, Lebanon

3) Faculty of Dental Medicine, Lebanese University, Beirut, Lebanon

Abstract

In 2017, the World Health Organization classified the odontogenic keratocyst as a developmental odontogenic cyst. The posterior parts of the mandible, especially the angle and the ramus, are the most involved sites. Due to their high recurrence rate, keratocysts are managed surgically with careful complete excision. Additionally, chemical solutions such as Carnoy's solution, modified Carnoy's solution, and 5-Fluorouracil have been associated with surgical treatment.

Diode lasers generate diverse wavelengths that have photothermal and photochemical special properties and could have some effects on the lining epithelium remnants of the cyst.

In this paper, we discuss a case of mandibular recurrent odontogenic keratocyst treated with 5-Fluorouracil topical application after enucleation and diode laser application with 18 years follow-up and teeth replacement with dental implant.

5-Fluorouracil and diode laser have been found to be very effective in the treatment of keratocysts.

Keywords: keratocyst, odontogenic cysts, mandible, diode laser, 5-Fluorouracil

Introduction

The odontogenic keratocyst (OKC) originates from residues of the dental lamina or extensions of the basal lining cell overlying the oral epithelium [1,2].

The posterior mandibular region, the angle and the ramus, are the most common affected sites, and the third molar is usually involved in greater lesions. A male-to-female ratio of 2:1 is noted [3,4]. OKCs are generally found during radiological examinations. In symptomatic cases, signs, and symptoms such as swelling, pain, infection, drainage, or paresthesia of the inferior alveolar nerve may be present [5]. Radiographically, OKCs appear as unilocular or multilocular radiolucent images with a well-defined peripheral radiopaque border. The borders are

frequently scalloped. Displacement of the mandibular canal can be observed, and root resorption is less frequent [4,5]. In some cases, rupture and perforation of cortical bone have been documented [6].

OKCs are managed surgically with careful complete excision due to their high recurrence rate. The thin and friable cyst lining is behind the surgical challenges of OKCs [7-9]. To avoid the recurrence potential of OKC, chemical solutions such as Carnoy's solution (CS) (1 g of ferric chloride (FeCl₃) dissolved in 6 mL of absolute alcohol, 3 mL of chloroform, 1 mL of glacial acetic acid), modified Carnoy's solution (MCS) (absolute alcohol 6 mL, chloroform 3 mL, glacial acetic acid 1 mL, ferric chloride 0.1 gm/mL), 5-Fluorouracil (5-FU) and liquid nitrogen cryotherapy have been associated with surgical treatment [7-12].

DOI: 10.15386/mpr-2067

Manuscript received: 04.02.2021

Received in revised form: 01.07.2021

Accepted: 15.07.2021

Address for correspondence:

Antoine Berberi

anberberi@gmail.com

This work is licensed under a Creative Commons Attribution-NonCommercial-NoDerivatives 4.0 International License

Moreover, the interactions of the different wavelengths of a diode laser can have photothermal and photochemical effects and could have some benefits on the lining epithelium remnants of the cyst [13-15].

In this report, we present a case of mandibular recurrent OKC treated by enucleation and application of topical 5-Fluorouracil and diode laser with 18 years follow-up; dental implants were also placed.

Case report

A healthy 25-year-old male, was oriented to our clinic, in 2002, complaining of a swelling in the left cheek. Extra-oral clinical exam revealed a left mandibular well limited hard swelling with submandibular adenopathy. Intraorally, a hard tumefaction that fills the buccal posterior area of the mandible was present; palpation showed a discontinuity of the lingual cortical bone. According to the patient who was under paracetamol the painful swelling dated few days back.

Panoramic X-ray revealed a precise extensive multilocular scalloped radiolucency surrounded by corticated borders with incomplete septa within the lesions. The lesion extends longitudinally from the posterior mandible to the second premolar anteriorly. Root resorption of the molars is

noted as well as a displacement of the mandibular canal to the basilar bone (Figure 1a).

Computed tomography (CT) scan images showed an osteolytic lesion in the left mandible including the angle, the ramus, and progressing toward the body with rupture of the continuity of both buccal and lingual cortices. Small and incomplete septa were also noticed (Figure 1b).

The clinical information and the radiological images oriented us towards a differential diagnosis between a dentigerous cyst, an OKC, and an ameloblastoma.

After discussion and written approval from the patient, an incisional biopsy was performed under local analgesia (Figure 1c). The histopathological examination showed the typical parakeratinized stratified squamous epithelial lining and the diagnosis of OKC was confirmed (Figure 1d).

The surgical enucleation of the inner lesion and extraction of both molars were performed; to avoid any possible surgical-related fracture of the mandible two arch bars were intermaxillary fixed before the surgery (Figure 1e).

The postoperative period was uncomplicated, the arch bars were removed one month later, and the recovery was smooth without any complications. The patient was followed monthly to observe the healing process and then yearly (Figure 1f).

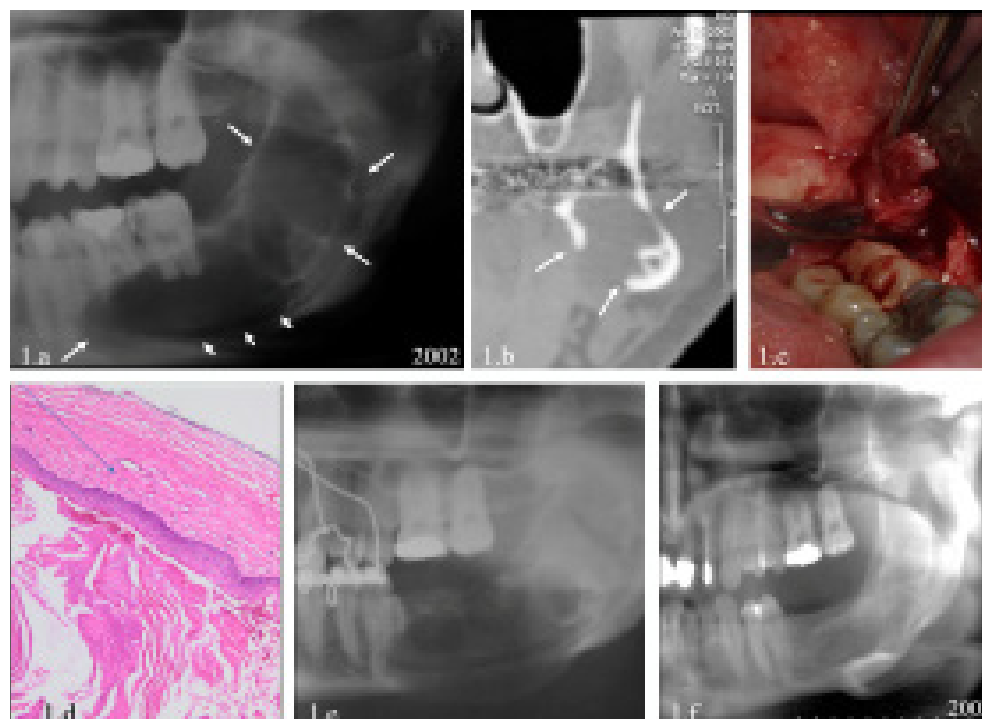


Figure 1. Mandibular odontogenic keratocysts (OKCs): **a.** Cropped panoramic radiograph shows a multilocular lesion in the posterior mandible and ramus (→) that determines basilar displacement of the mandibular canal (→), small and incomplete internal septum and root resorption. **b.** Para-axial reconstruction image of CT scan: perforation of the lingual cortex (→), reduction in the thickness of the buccal cortex, and the basilar position of the mandibular canal. **c.** Incisional biopsy of the lesion. **d.** Histological image shows the typical parakeratinised stratified squamous epithelial lining (HE 40 X). **e.** Immediate post-operative cropped panoramic radiograph with the arch bars placed in the mandible and maxilla with inter-maxillary fixation. **f.** One-year cropped panoramic radiograph.

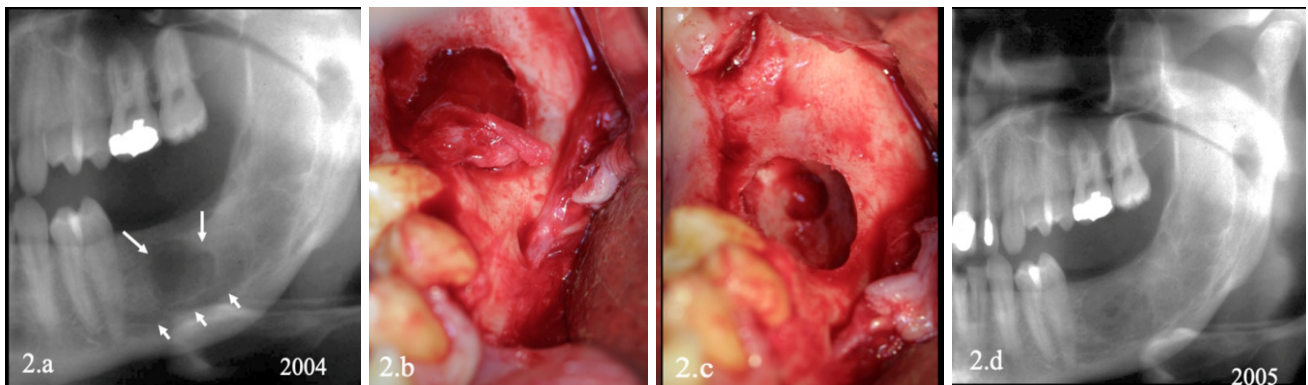


Figure 2. **a.** Two-years (2004) cropped panoramic radiograph showing a mono-ocular radiolucency (→) and the mandibular canal still in a basilar position (→). **b.** Enucleation of the lesion, the mental nerve was intact. **c.** The bony cavity after enucleation and note the small inside bony cavity. **d.** One-year (2005) cropped panoramic radiograph showing the bone healing of the lesion after second surgery.

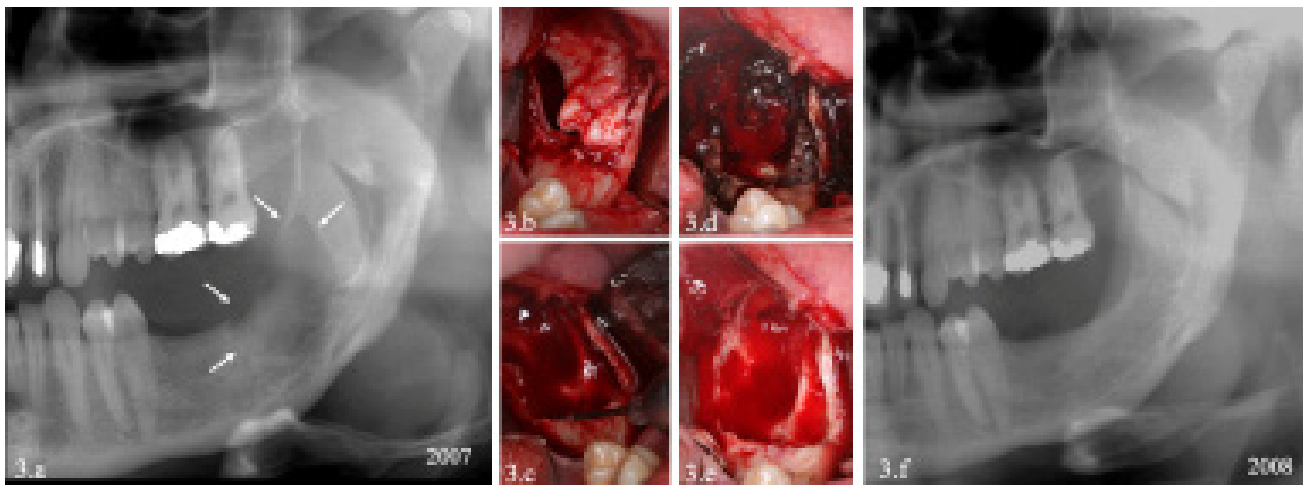


Figure 3. **a.** Two-years (2007) cropped panoramic radiograph showing the new lesion in the ramus (→). **b.** Enucleation of the lesion. **c.** Diode laser application. **d.** 5-FU application. **e.** Cavity after cleaning. **f.** One-year (2008) after third intervention and 6 years after first surgery cropped panoramic radiograph revealing a remission of the cystic lesion.

Two years later, the panoramic radiograph showed a mono-ocular radiolucency located around the extracted molars area (Figure 2a). The new lesion was enucleated under local analgesia and histopathological examination confirmed the OKC recurrence diagnosis (Figure 2b and 2c).

In 2007 a control panoramic radiograph revealed the same old lesion, but located in the ramus. Following this second recurrence, a new surgical protocol was adopted consisting of the application after enucleation of 5-FU and diode laser; a thorough curettage and bone osteoplasty of the cystic cavity were also performed.

The diode laser (ILASE®, BIOLASE, Inc.27042 Towne Centre Drive, Suite 270, Foothill Ranch, CA 92610-2811 USA) emitting a 940 nm wavelength in 5 W pulsed, with a pulse duration 0.5 ms, using a fiber tip of 200 µm

diameter, was used for its photochemical properties while the application advantage of 5-FU (Efudex® 5% Bausch Health US, LLC) solution was through its chemical properties; 5-FU was applied to the cyst area for 5 min followed by thorough irrigation to eliminate the possible lining epithelium remnants before closing the flaps with interrupted sutures (Figures 3a, 3b, 3c, 3d, 3e and 3f).

All the control panoramic radiographs till 2015 showed complete healing of the posterior part of the mandible. Two dental implants were then placed to substitute the extracted first and second molars (Figures 4a, 4b, and 4c).

In 2020, 18 years after the treatment of the first lesion, the panoramic radiograph revealed a successful healing process and two functional dental implants (Figure 4d).

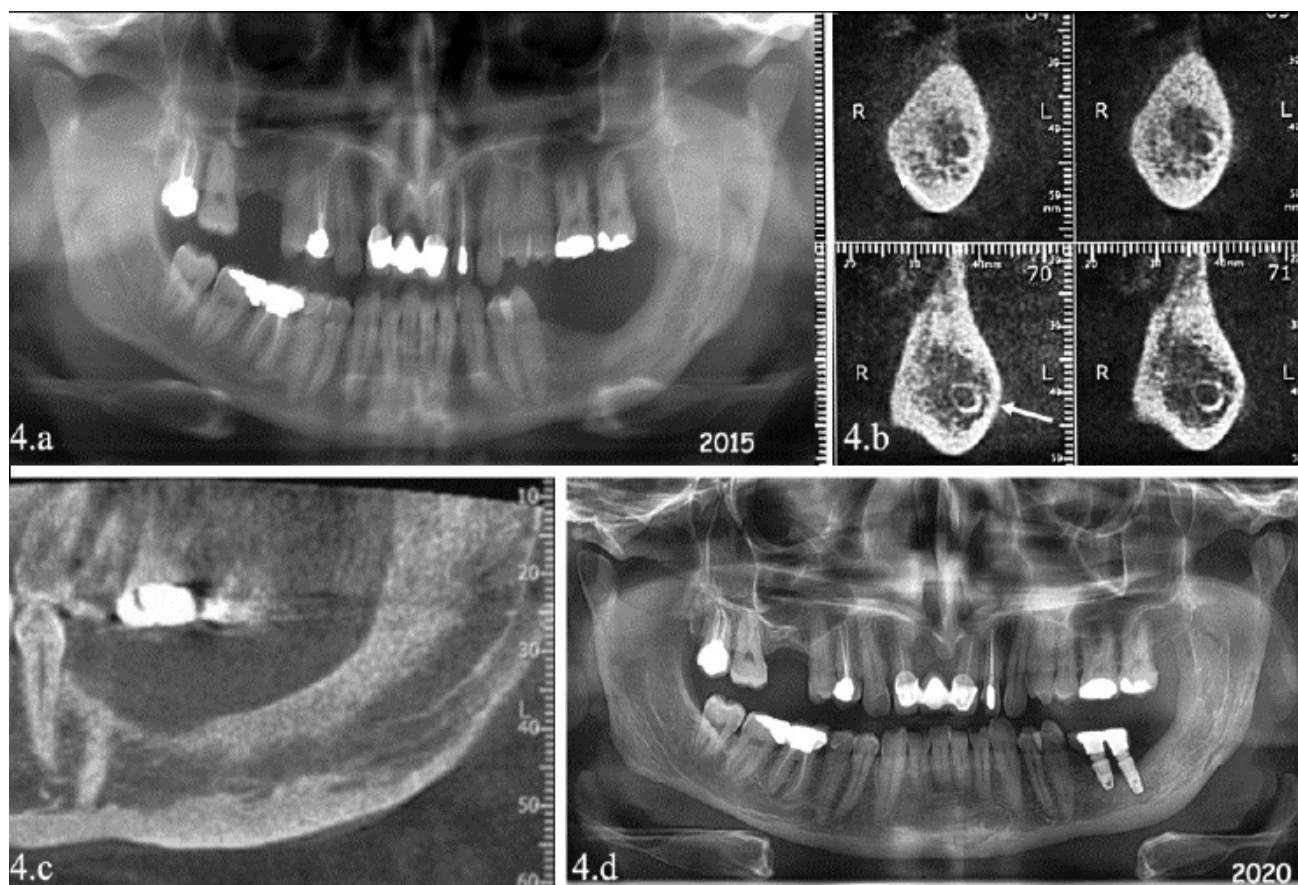


Figure 4. a. Eight-years (2015), after the third surgery: cropped panoramic radiograph showing complete remission of the mandibular bone. b. Para-axial reconstruction image of CT scan: complete bone formation and the new position of the mandibular canal (→). c. Sagittal reconstruction image of CT scan showing bone healing in the body, angle and ramus of the mandible. d. Panoramic radiograph, 18 years after (2020), showing complete remission of the mandibular bone with two-implant placed to restore the extracted molars.

Discussion

Recurrence of OKCs is triggered by inadequate elimination of the epithelial remnants from the lining of the cyst, satellite and/or microcyst, and remnants left in the basal cell layer of the oral epithelium [2,7-9].

OKC lining is very thin and is easily ruptured especially in larger cystic lesions. Consequently, recurrence may be dependent on the treatment modality and its success. Thus there have been numerous attempts to decrease the high recurrence rate by refining the surgical techniques [7-10].

Al-Moraissi et al. (2017) stated that the recurrence rate related to numerous treatment techniques was as follows: a) marsupialization (32.3%), b) enucleation (23.1%), c) enucleation with curettage (17.4%), d) enucleation plus liquid nitrogen cryotherapy (14.5%), e) decompression associated with a residual cystectomy (14.6%), f) enucleation and CS (11.5%), and g) resection (8.4%) [9].

Akhter Lone et al. (2020) investigated the usefulness of 5-FU in OKC. For them, when applied topically in OKC, it induced less postoperative morbidity than enucleation followed by application of MCS [16].

Isola et al. (2017) showed that the use of diode laser in the treatment of lateral periodontal cyst accelerates healing time and could be adopted for surgical treatment for the epithelial developmental odontogenic cysts [14].

The radiographs of the clinical case showed root resorption, which is an unusual finding of OKCs, with a stated frequency varying from 1.3 to 11% as described by Chirapathomsakul et al. [17]. Additionally, the discontinuity of the cortical lingual bone is an infrequent feature of OKCs, with a prevalence variable from 39 to 51%; the rupture of the two cortices, buccal, and lingual, was observed in our case [17].

In our treatment protocol, the combination consisting of: a) the lesion enucleation and curettage, b) the bone osteoplasty, c) the use of a diode laser 940 nm on

the soft tissue, and d) the application of the 5-FU solution on the affected area followed by thorough irrigation has succeeded in eliminating the risk of recurrence.

The panoramic X-ray, after 12 years, confirms the bone healing in the old cystic area.

Conclusion

The combination consisting of 5-FU and its chemical effects and diode laser and its photochemical properties deemed to be helpful on decreasing the recurrence process of OKC by having a direct action on the epithelial remnants from the lining of the cyst. However, further clinical research is essential to generate more evidence on the use of this combination as adjuvant treatment of OKC.

References

1. Wright JM, Vered M. Update from the 4th Edition of the World Health Organization Classification of Head and Neck Tumours: Odontogenic and Maxillofacial Bone Tumors. *Head Neck Pathol.* 2017;11:68-77.
2. Rajendra Santosh AB. Odontogenic Cysts. *Dent Clin North Am.* 2020;64:105-119.
3. Sansare K, Raghav M, Mupparapu M, Mundada N, Karjodkar FR, Bansal S, et al. Keratocystic odontogenic tumor: systematic review with analysis of 72 additional cases from Mumbai, India. *Oral Surg Oral Med Oral Pathol Oral Radiol.* 2013;115:128-39. doi: 10.1016/j.oooo.2012.10.005. Erratum in: *Oral Surg Oral Med Oral Pathol Oral Radiol.* 2013;115:841-842.
4. Schuch LF, de Arruda JAA, Mosconi C, Kirschnick LB, Pinho RFC, Viveiros SK, et al. A Brazilian multicentre study of 2,497 isolated cases of odontogenic keratocysts. *Oral Dis.* 2020;26:711-715.
5. Borghesi A, Nardi C, Giannitto C, Tironi A, Maroldi R, Di Bartolomeo F, et al. Odontogenic keratocyst: imaging features of a benign lesion with an aggressive behaviour. *Insights Imaging.* 2018;9:883-897.
6. Alves DBM, Tuji FM, Alves FA, Rocha AC, Santos-Silva ARD, Vargas PA, et al. Evaluation of mandibular odontogenic keratocyst and ameloblastoma by panoramic radiograph and computed tomography. *Dentomaxillofac Radiol.* 2018;47:20170288.
7. Dias G, Marques T, Coelho P. Treatment options for keratocyst odontogenic tumor (KCOT): a systematic review. *Oral Surgery.* 2017;10:193-209.
8. Kinard B, Hansen G, Newman M, Dennis P, Haefls T, Perez S, et al. How well do we manage the odontogenic keratocyst? A multicenter study. *Oral Surg Oral Med Oral Pathol Oral Radiol.* 2019;127:282-288.
9. Al-Moraissi EA, Dahan AA, Alwadeai MS, Oginni FO, Al-Jamali JM, Alkhatari AS, Al-Tairi NH, Almaweri AA, Al-Sanabani JS. What surgical treatment has the lowest recurrence rate following the management of keratocystic odontogenic tumor?: A large systematic review and meta-analysis. *J Craniomaxillofac Surg.* 2017;45:131-144.
10. Dashow JE, McHugh JB, Braun TM, Edwards SP, Helman JI, Ward BB. Significantly Decreased Recurrence Rates in Keratocystic Odontogenic Tumor With Simple Enucleation and Curettage Using Carnoy's Versus Modified Carnoy's Solution. *J Oral Maxillofac Surg.* 2015;73:2132-2135.
11. Caminiti MF, El-Rabbany M, Jeon J, Bradley G. 5-Fluorouracil Is Associated With a Decreased Recurrence Risk in Odontogenic Keratocyst Management: A Retrospective Cohort Study. *J Oral Maxillofac Surg.* 2021;79:814-821.
12. Ledderhof NJ, Caminiti MF, Bradley G, Lam DK. Topical 5-Fluorouracil is a Novel Targeted Therapy for the Keratocystic Odontogenic Tumor. *J Oral Maxillofac Surg.* 2017;75:514-524.
13. Knappe V, Frank F, Rohde E. Principles of lasers and biophotonic effects. *Photomed Laser Surg.* 2004;22:411-417.
14. Isola G, Matarese G, Lo Giudice G, Briguglio F, Alibrandi A, Crupi A, et al. A New Approach for the Treatment of Lateral Periodontal Cysts with an 810-nm Diode Laser. *Int J Periodontics Restorative Dent.* 2017;37:e120-e129.
15. De Falco D, Di Venere D, Maiorano E. An Overview of Diode Laser-Assisted Oral Surgery. *Cureus.* 2020;12:e9297.
16. Akhter Lone P, Ahmed Wani N, Ahmed Janbaz Z, Bibi M, Kour A. Topical 5-fluorouracil application in management of odontogenic keratocysts. *J Oral Biol Craniofac Res.* 2020;10:404-406.
17. Chirapathomsakul D, Sastravaha P, Jansisyanont P. A review of odontogenic keratocysts and the behavior of recurrences. *Oral Surg Oral Med Oral Pathol Oral Radiol Endod.* 2006;101:5-9; discussion 10.