



Anastomosis between the facial nerve – ansa cervicalis and the facial nerve – hypoglossal nerve in rabbits: technical note for a practical use in peripheral facial palsy

Georgeta Magdalena Balaci^{1,2}, Zoltan Zsigmond Major^{3,4},
Oana Maria Radu^{1,5}, Raul Sălăgean², Ioan Ștefan Florian^{1,2}

1) Iuliu Hatieganu University of Medicine and Pharmacy, Cluj-Napoca, Romania

2) Department of Neurosurgery, Emergency County Hospital, Cluj-Napoca, Romania

3) Department of Neurology, Clinical Municipal Hospital, Cluj-Napoca, Romania

4) Department of Neurophysiology, National Center for Spinal Disorders, Budapest, Hungary

5) Department of Neurosurgery, Division of Neurosurgical Anesthesiology, Emergency County Hospital, Cluj-Napoca, Romania

Abstract

Background and aims. To emphasize the importance of laboratory dissections in perfecting surgical techniques. In this paper, we describe the technical details on rabbit dissection for practical applications.

Methods. Four New Zealand rabbits were distributed into two groups and underwent anastomosis between the Facial Nerve and Ansa Cervicalis (group 1) and between the Facial Nerve and Hypoglossal Nerve (group 2). They were clinically and neurophysiologically evaluated after ten weeks. Electroneurography with skin electrodes were used to identify the motor activity of the involved muscles and nerves. Facial and ipsilateral tongue reinnervation was analyzed 40 weeks after anastomosis. Evoked electromyographic muscle tension was used to evaluate facial and tongue reinnervation.

Results. Facial and ipsilateral tongue reinnervation was analyzed 40 weeks after anastomosis. Recorded evoked potentials showed improvement in facial reinnervation in all four rabbits. Rabbits undergoing FN-HN anastomosis still showed ipsilateral lingual paresis, based on EMG tests. The survival rate was 100%.

Conclusions. The laboratory dissection plays a crucial role in training surgical specialists to achieve favorable patient outcomes. Both types of anastomosis can be used to achieve facial reinnervation; however, it is imperative to prevent ipsilateral lingual paralysis that may arise from using the hypoglossal nerve.

Keywords: anastomosis, neurorrhaphy, facial nerve, hypoglossal nerve, ansa cervicalis, rabbit dissection, facial palsy

DOI: 10.15386/mpr-2665

Manuscript received: 17.08.2023

Received in revised form: 25.08.2023

Accepted: 14.09.2023

Address for correspondence:
Georgeta Magdalena Balaci
balacimagdalena@yahoo.com

This work is licensed under a Creative Commons Attribution-NonCommercial-NoDerivatives 4.0 International License <https://creativecommons.org/licenses/by-nc-nd/4.0/>

Background and aims

Damage to the seventh cranial nerve can cause facial paralysis. Many skull base surgical procedures may lead to cranial nerve deficits among which facial nerve paresis or outright paralysis are the most common and severe. Facial paralysis results in difficulty with basic facial function, such as smiling, closing eyelids, eating, and speaking, leading to facial asymmetry and potential irreversible damage. Early treatment is crucial to prevent complications, in

particular ocular ones, and minimize the severe psychological impact on patients.

Facial symmetry is conclusive for aesthetic appeal, but achieving it can be challenging for surgeons due to the various causes of facial asymmetry, including neuromuscular changes, soft tissue, bone fractures, or mixed origin.

The main treatment method for severe facial paralysis is anastomosis of its peripheral branches with a neighboring proximal nerve section usually from another cranial nerve.

Anastomosis between the facial nerve (FN) and accessory nerve (AN) was first attempted by Dr. Faure of the Hôpital Laënnec in Paris (1898) [1], which then led to the inception of new surgical approaches for facial asymmetry. Over the past 70 years, authors including Coomes [2], Sultaneh [3], Beutner [4], and their colleagues have made significant contributions in the field of peripheral facial palsy recovery.

The axonal structure of ansa cervicalis has an effective role in achieving facial reinnervation [5], as other techniques also have, such as cross-face nerve grafting [6], masseter to facial cranial nerve anastomosis [7], and free muscle transfer for dynamic reconstruction [8]. Although the end-to-end anastomosis between FN and hypoglossal nerve (HN) has been used for facial muscle reinnervation since Körte proposed it in 1903, its ipsilateral tongue atrophy complication remains a controversial topic [9].

The surgical technique's development requires precise knowledge of nerves anatomy and their relationships with nearby vascular structures, obtained through animal models. Compared to rodents, rabbits have numerous phylogenetic components closer to human beings and possess a remarkable topographical resemblance to humans in the latero-cervical area, thus establishing them as a highly viable experimental model.

Several genetic examinations have paved the way in support of utilizing rabbits as opposed to smaller or larger-sized species. Additional advantages are given by the availability of rabbits in the research laboratory: their affordability (compared to other larger species), short time of reproduction, and brief period of life, and they may also be used in simultaneous studies (as long as they do not block the anticipated outcomes) [10].

Providing anatomic fidelity compared to humans, rabbit dissections imply the development of technical skills with no risk to patients. Despite the fact that it provides a deep and narrow operative field, knowledge of the anatomical components is precisely related to the success of the anastomosis. This technical report describes the practical steps for performing anastomosis between the FN and ansa cervicalis (AC) and anastomosis between the FN and HN in rabbits.

Methods

This research was approved by the Ethical Committee of Iuliu Hatieganu University of Medicine and Pharmacy, Cluj-Napoca, no.132/15.03.2018 and the experiments were conducted with respect to the 3Rs Principles [11] of Laboratory Animals.

Animals

Four (4) New Zealand adult rabbits, male and female, weighing 2 to 3 kg, were kept in a quarantine room (warm temperature, no stress condition) three hours prior to surgery. It is imperative to maintain room temperature within the range of 23°C to 25°C at all times.

Studies [12] strictly uphold the policy of only fasting

rabbits for a maximum of 4 to 6 hours. The rabbits were given access to water until 1 to 2 hours before the induction process to ensure their optimal health and well-being.

Anesthesia

Intubation was achieved by injectable induction through intravenous routes. A catheter was placed in the lateral ear vein for injectable induction. Our team utilizes the non-rebreathing system to ensure optimal surgical conditions, maintaining a 500 mL oxygen flow rate. With a non-rebreathing system, the depth of anesthesia can be rapidly altered. As part of our commitment to safety, we carefully monitored the inhalant anesthetic, ensuring that it remained at 1% or lower during surgical preparation.

If respiratory rates decreased, we promptly adjusted the vaporizer setting and intermittently compressed the bag to prevent overinflation [13]. In our experience, we have found that isoflurane is the preferred inhalant anesthetic for rabbits.

A mix was used for mild anesthesia: Midazolam, at 1 to 2 mg/kg for muscle relaxation, and Butorphanol, at 0.4 mg/kg for analgesia, given intramuscularly. For deep anesthesia a combination of ketamine (20 mg/kg) and midazolam 0.5 mg/kg was used. Rabbits were intubated in the lateral position through a direct visualization technique using a single-use pediatric endotracheal tube; afterward, they were connected to a rebreathing anesthetic circuit. Deep anesthesia was obtained with inhalant anesthetic (sevoflurane) and the concentration was adjusted for surgical needs. Sterile 0.9% saline solution was intravenously administered (20 ml/h) during surgery [14]. The anesthesiologist carefully monitored the respiratory rate and heart rate during anesthesia. The heart rate of a conscious rabbit can vary significantly, ranging from 125 to 325 beats per minute, depending on the animal's size and level of stress.

When anesthetized, the heart rate may fluctuate due to the administered medication. If the heart rate drops, it may indicate that the animal is under too deep an anesthesia, which can cause a decrease in respiratory rate. A conscious rabbit typically takes 30 to 60 breaths per minute, and it is crucial to monitor their breathing closely to ensure proper functioning. Any increase in the effort the rabbit is putting in to breathe or a decrease in rebreathing bag movements may be a sign of an obstructed endotracheal tube [15].

Surgical technique (Figures 1 a-c, 2 d-f)

After being given the anesthetic, the rabbit was positioned on its side with its head slightly extended to provide better access to the cervical region. Muscle activations were recorded using the neuromonitoring system. The electrodes were inserted in the masseter muscle (for the facial nerve), the sternothyroid and sternohyoid (for ansa cervicalis), and in the tongue (for the hypoglossal nerve). At the lateral cervical area, a portion of the fur, 5/3 cm, was shaved, starting from the ear toward the anterior region of the neck, at 1 cm inferior to the mandible. The area was disinfected using a povidone-iodine solution and enclosed by sterile surgical fields to ensure proper isolation.

Anastomosis between FN-AC

Using the intraoperative microscope, a linear incision was made starting from the level of the ear. The stylomastoid foramen was identified in the upper portion of the incision, and the FN was carefully dissected from the surrounding tissues up to the level of its zygomatic and mandibular branches. Special attention was given to the parotid gland, which can be easily sectioned. To locate the AC, deep planes were dissected, starting with the removal of the cervical fascia and continuing with the dissection of the anterior edge of the cleidomastoid muscle. This highlights the anterior edge of the sternocephalic muscle and the vascular-nerve bundle, which includes the internal jugular vein (IJV), common carotid artery (CCA), and superior branch of the AC. The neuromonitoring system was used to accurately identify the FN and AC. The FN was sectioned at the level of the stylomastoid foramen, while the AC was cut at the

level of its branching within the sternothyroid muscle. The FN was retracted inferiorly to the AC, and neurorrhaphy was performed using two 9-0 nylon sutures.

Anastomosis between FN-HN

The technique for dissecting and sectioning the FN was similar to the previous method. The HN was identified at the mandibular angle and immediately sectioned after the division of the descending branch of the AC from the main trunk of the HN. It is crucial to section the HN before it passes under the facial artery toward the geniohyoid muscle due to the risk of facial artery injury. The FN was retracted inferiorly to the HN for the neurorrhaphy in the same way.

The wounds were sutured using 4-0 Vicryl for the subcutaneous layers and 3-0 absorbable intradermal sutures. The wounds were covered with pads and held in place using adhesive tape.

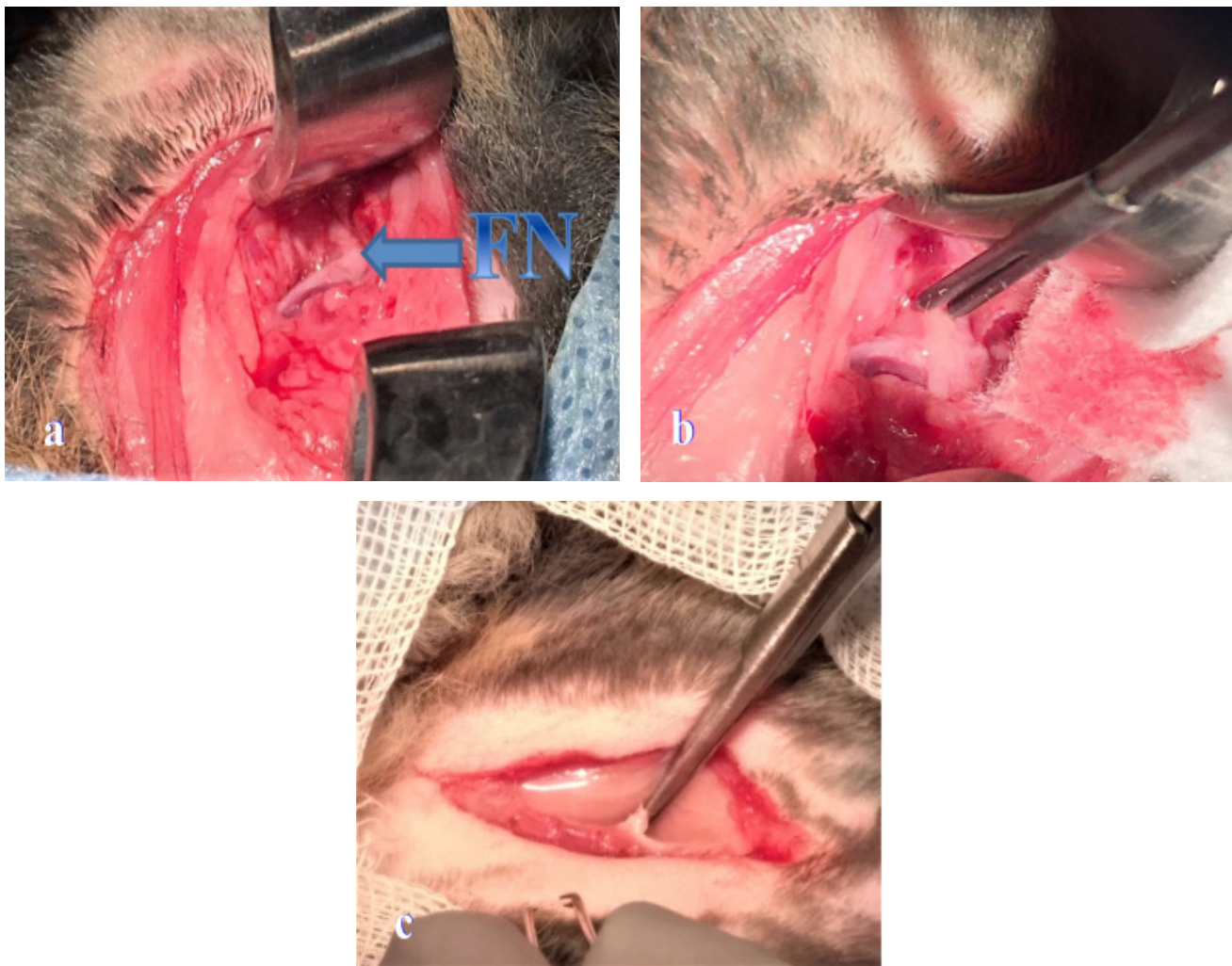


Figure 1. a) The FN at the exit point of the stylomastoid foramen (blue arrow); b) Identifying FN can be accomplished using a neuromonitoring system; c) Before dividing into the two branches (zygomatic and mandibular), it is necessary to section the FN.

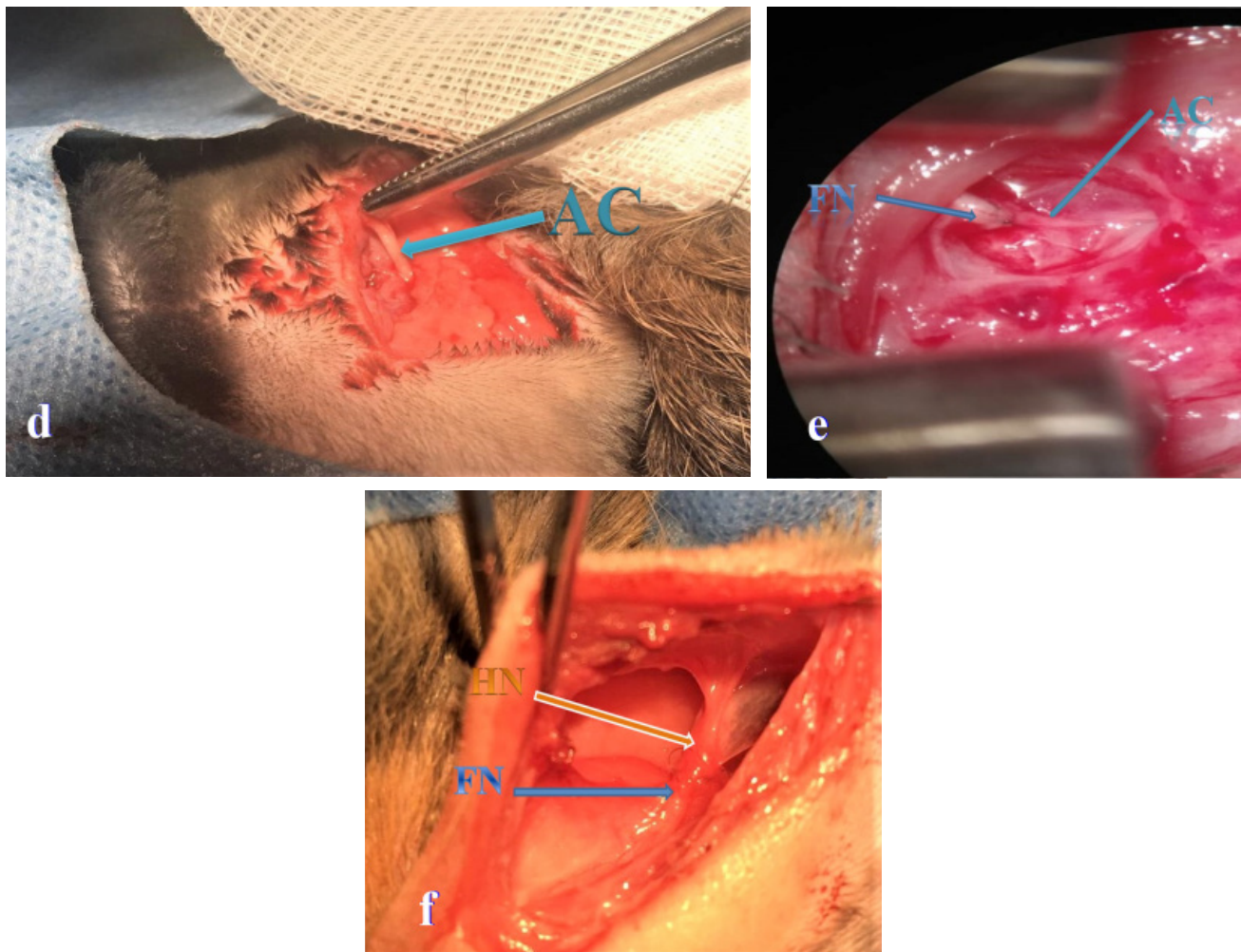


Figure 2. **d)** The AC (green arrow) must have a sufficient length - up to 2 centimeters for a tension-free anastomosis; **e)** Anastomosis between the FN and AC; **f)** Anastomosis between the FN and HN (orange arrow).

Recovery

All four rabbits survived the experiment. If ketamine was used intramuscularly, the effects of xylazine sedation were not reversed. It is crucial to monitor pain in rabbits; they do not vocalize when in pain. The opioid buprenorphine was given by injection every 8 hours, at a dosage of 0.01 to 0.03 mg/kg. This medication has long-lasting pain-relieving effects and causes minimal sedation. Providing a stress-free environment and adequate heat is essential for a rabbit's successful recovery. We ensured that the rabbits were active and consuming food, as a top priority.

Results

Four New Zealand rabbits underwent surgery, with two receiving anastomosis between FN and AC, and the other two receiving anastomosis between FN and HN. Immediately postoperatively, in all four rabbits total

facial paresis was observed, while the rabbits that received anastomosis between FN and HN also showed ipsilateral lingual paresis.

There were no complications related to the wounds that could affect facial reinnervation. Once every four weeks clinical assessments were conducted to closely observe the movement, tonicity, and the blinking reflex of the affected side's facial muscles in comparison to the normal side.

Facial and ipsilateral tongue reinnervation was analyzed 40 weeks after anastomosis. Surface electromyography (EMG) electrodes were precisely placed on both the masseter muscle and tongue. Anesthesia was induced using ketamine and xylazine intramuscularly. Evoked EMGs were recorded on a signal average. Recorded evoked potentials showed improvement in facial reinnervation in all four rabbits. Despite not being the primary focus of this technical note, it is essential to

note that rabbits undergoing FN-HN anastomosis still showed ipsilateral lingual paresis, based on EMG test. This demonstrates the superior effectiveness of FN-AC anastomosis.

Discussion

Although there are various operative techniques for peripheral facial paralysis recovery, anastomosis between the facial nerve and ansa cervicalis as well as anastomosis between the facial nerve and hypoglossal nerve, are among the effective options. Patients with facial paralysis grades IV-VI House & Brackmann may be candidates for anastomosis to augment self-esteem and social reintegration. Four New Zealand rabbits were studied for these anastomoses, with two undergoing facial nerve-ansa cervicalis anastomosis and the other two undergoing facial nerve-hypoglossal nerve anastomosis.

The selection of this model was based on its effortless assessment of nerve and muscular tissue functionality and the uncomplicated surgical procedures entailed. Providing anatomic fidelity compared to humans, rabbit dissections allow for the development of technical skills with no risk to patients. Despite the fact that it provides a deep and narrow operative field, knowledge of the anatomical components is precisely related to the success of the anastomosis.

Studies recommend sectioning the facial nerve immediately after it exits the stylomastoid foramen, as the proximal part has a higher rate of reinnervation than the distal part [16]. Facial movements function signs were unequivocally recorded within the first ten weeks of our study, aligning with the findings of comparable studies [17,18]. Although it represents a strong motor component, sectioning the HN, known as the motor nerve of the tongue, leads to the appearance of ipsilateral lingual paresis and swallowing disorders. These complications exacerbate existing symptoms. The rabbits that underwent anastomosis between the FN and HN still showed ipsilateral lingual paresis twelve weeks after the procedure.

Utilizing the AC is a preferable option to prevent any potential complications despite the lower motor capacity of the facial reinnervation compared to HN [19]. Two factors are essential to achieve a viable anastomosis: the tension-free anastomosis and the neurorrhaphy should be performed at two diametrically opposite points.

Understanding the macrostructure is an essential factor for scientific advancement. The cervical region of a rabbit bears striking similarities to that of a human, rendering it highly valuable for medical research and real-life medical scenarios.

Expanding the visualization of peripheral nerves can provide significant clinical benefits in various surgical fields, including neurosurgery and otolaryngology. This technique should be considered a valuable tool for enhancing surgical outcomes and improving patient care.

The benefits of using laboratory dissection in surgical specialties are clear. Practicing technical skills in a safe, controlled environment reduces patient risk and helps healthcare professionals through the early stages of their careers.

Conclusions

Facial reinnervation occurred after both anastomoses, but ipsilateral lingual paresis is a complication to be avoided. Utilizing the AC is a preferable option to prevent any potential complications. Previous knowledge influences how people approach new techniques. The learning process, considered a lifelong continuing form of education, improves with years of experience. The practice gained by research laboratory dissection represents an important stage of education through which people learn to practice as future qualified healthcare professionals. Early indications and optimal technical completion of the surgical procedures are prerequisites for attaining excellent outcomes.

Acknowledgements

The authors are grateful to Dr. Septimiu Toader for his invaluable help and technical assistance.

References

1. Cushing H. I. The Surgical Treatment of Facial Paralysis by Nerve Anastomosis: With the Report of a Successful Case. *Ann Surg.* 1903;37:641-659.
2. Coomes EN. Electrodiagnostic findings in clonic facial spasm and in facio-hypoglossal anastomosis. *Ann Phys Med.* 1965;8:48-57.
3. Sultaneh A, Makhmudov UB, Naïdin VL, Cherekaev VA. 1-stage plastic repair of the facial nerve using the trunk of the hypoglossal nerve and reinnervation of the latter with a branch of the cervical loop. *Zh Vopr Neurokhir Im N N Burdenko.* 1995;1:34-36.
4. Beutner D, Grosheva M. Reconstruction of complex defects of the extracranial facial nerve: technique of “the trifurcation approach”. *Eur Arch Otorhinolaryngol.* 2019;276:1793-1798.
5. Tayebi Meybodi A, Moreira LB, Zhao X, Belykh E, Lawton MT, Eschbacher JM, et al. Using the Post-Descendens Hypoglossal Nerve in Hypoglossal-Facial Anastomosis: An Anatomic and Histologic Feasibility Study. *Oper Neurosurg (Hagerstown).* 2020;19:436-443.
6. Daeschler SC, Zuker R, Borschel GH. Strategies to Improve Cross-Face Nerve Grafting in Facial Paralysis. *Facial Plast Surg Clin North Am.* 2021;29:423-430.
7. Zotov AV, Rzaev JA, Chernov SV, Dmitriev AB, Kalinovsky AV, Spallone A. Masseter-to-Facial Cranial Nerve Anastomosis: A Report of 30 Cases. *Oper Neurosurg (Hagerstown).* 2020;19:502-509.

8. Dong A, Zuo KJ, Papadopoulos-Nydam G, Olson JL, Wilkes GH, Rieger J. Functional outcomes assessment following free muscle transfer for dynamic reconstruction of facial paralysis: A literature review. *J Craniomaxillofac Surg.* 2018;46:875-882.
9. Han JH, Suh MJ, Kim JW, Cho HS, Moon IS. Facial reanimation using hypoglossal-facial nerve anastomosis after schwannoma removal. *Acta Otolaryngolog.* 2017;137:99-105.
10. Fan J, Watanabe T. Transgenic rabbits as therapeutic protein bioreactors and human disease models. *Pharmacol Ther.* 2003;99:261-282.
11. Tannenbaum J, Bennett BT. Russell and Burch's 3Rs then and now: the need for clarity in definition and purpose. *J Am Assoc Lab Anim Sci.* 2015;54:120-132.
12. Harkness JE, Wagner JE. *The Biology and Medicine of Rabbits and Rodents.* (4th ed 4). Philadelphia, PA: Lea & Febiger, 1989, p.23-44.
13. Flecknell PA. Anesthesia and analgesia for rodents and rabbits. In: Laber-Lalrd K, Swindle MM, Flecknell PA, (eds). *Handbook of Rodent and Rabbit Medicine*, New York, NY: Pergamon, 1996, p. 219-237.
14. Mason DE. Anesthesia, analgesia, and sedation for small mammals In: Hillyer EV, Quesenberry KE, (eds). *Ferrets, Rabbits, and Rodents: Clinical Medicine and Surgery* Philadelphia, PA: Saunders, 1997, p. 378-391.
15. Harvey RC, Walberg J Special considerations for anesthesia and analgesia in research animals. In: Short CE, (ed). *Principles and Practice of Veterinary Anesthesia.* Baltimore, MD: Williams & Wilklns, 1987, p. 380-392.
16. Colli BO. General aspects of acute traumatic injuries of peripheral nerves [Aspectos gerais das lesões traumáticas agudas nos nervos periféricos]. *Arquivos Brasileiros de Neurocirurgia.* 1993;12:171-200. Portuguese
17. Torvik A, Söreide AJ. Nerve cell regeneration after axon lesions in newborn rabbits. Light and electron microscopic study. *J Neuropathol Exp Neurol.* 1972;31:683-695.
18. Spector JG, Lee P, Derby A. Rabbit facial nerve regeneration in autologous nerve grafts after antecedent injury. *Laryngoscope.* 2000;110:660-667.
19. Lamas G, Lannadère E, Tankéré F, Truong Tan T, Bernat I, Gatignol P. Termino-terminal hypoglossofacial anastomosis, indications, results. *Rev Laryngol Otol Rhinol (Bord).* 2010;131:97-102.