



SURGERY

A rare case of Wilkie's syndrome with infantile hypertrophic pyloric stenosis

Petar Stamov¹, Sylvia Stamova²

1) Department of General and Operative Surgery, Medicine Faculty, Medical University of Varna, Bulgaria

2) Department of Pharmaceutical Chemistry, Pharmacy Faculty, Medical University of Varna, Bulgaria

Abstract

Wilkie's syndrome is a rare clinical disorder characterized by partial or complete obstruction of the duodenum. Infantile hypertrophic pyloric stenosis (IHPS) is defined as hyperplasia of the smooth muscle fibers of the pylorus, which is considered responsible for narrowing the pyloric canal and eventually obstructing the gastric outlet. This paper presents a case of a 3-month-old boy who had been vomiting after feeding for one month. The main symptoms, postprandial vomiting, dehydration, alkalosis, and weight reduction, point to the IHPS disease. Imaging studies also confirmed the diagnosis. During the surgical treatment, a concomitant condition known as Wilkie's syndrome was also evidenced. The team performed a complex surgical treatment of a patient diagnosed with both Wilkie's syndrome and IHPS within one single surgical operation. Surgical treatment with pyloromyotomy and duodenal-duodenal anastomosis within one operation is an optimal option for one-stage treatment of patients with IHPS and Wilkie's syndrome.

Keywords: Wilkie's syndrome, infantile hypertrophic pyloric stenosis

Introduction

The Wilkie's syndrome, also known as Superior Mesenteric Artery Syndrome (SMAS), is a rare clinical disorder characterized by partial or complete obstruction of the duodenum. The disease was first described by Carl Von Rokitansky in 1861 in a postmortem case, which was later studied in detail by Wilkie in 1927 [1]. Less than 500 cases of Wilkie's syndrome have been reported in the literature, with an estimated incidence of 0.013% to 0.3%. It occurs more frequently among females in a ratio of 2:1 [2,3] with peaks between the second and third decades.

The etiological aspect of the disease is related to the compression of the third portion of the duodenum between the abdominal aorta and the superior mesenteric artery, leading to duodenal obstruction and severe malnutrition. The main symptoms of the syndrome are postprandial epigastric pain, emesis, malnutrition, significant weight loss and anorexia. Diagnosis of

SMAS has many challenges. However, it may be based on apparent clinical signs confirmed with abdominal X-ray (AXR). Treatment of SMAS can be conservative and/or surgical [4,5].

Infantile Hypertrophic Pyloric Stenosis (IHPS) is defined as hyperplasia of the smooth muscle fibers of the pylorus, which is considered responsible for narrowing of the pyloric canal and eventually obstruction of the gastric outlet. The most common symptoms of IHPS are non-bilious vomiting, dehydration, weight loss; and characteristic hypochloremic and hypokalemic metabolic alkalosis. In 33.3% of cases with IHPS, the classic olive-shaped mass is present in the patient's abdomen, but in two-thirds of the cases the olive-shaped mass is not found [6,7]. The optimal treatment for infantile hypertrophic pyloric stenosis (IHPS) is the Fredet-Ramstedt extramucosal pyloromyotomy, which is considered the gold standard procedure.

DOI: 10.15386/mpr-2724

Manuscript received: 06.03.2024

Received in revised form: 01.06.2024

Accepted: 15.06.2024

Address for correspondence:

Sylvia Stamova

sylvia.stamova@yahoo.com

This work is licensed under a Creative Commons Attribution-NonCommercial-NoDerivatives 4.0 International License <https://creativecommons.org/licenses/by-nc-nd/4.0/>

Case presentation

This paper presents a case of a 3-month-old boy who had been vomiting after feeding for one month. The vomiting, in the beginning, was non-bilious with smaller quantities, but over time it turned to projectile vomiting. The vomiting materials were mostly white with the appearance of curdled milk and sometimes yellowish. The baby was born naturally with a weight of 3160 g, without perinatal problems. At 7 weeks of age, he began to vomit, almost after every feeding with 6-7 episodes per day. The patient has not gained weight in the last month and was admitted with a weight of 3240 g. Defecation was reduced to one defecation in 3-4 days. Before admission to the Department of Pediatric Surgery, the patient was hospitalized earlier in the Pediatric Department with the same complaints and symptoms mentioned above.

On physical examination: a 3-month-old male patient, non-febrile on admission; dry skin with reduced turgor and elasticity; bilateral vesicular breathing without wheezing; rhythmic heartbeat; weak systolic sound; pulse rate of 120/min.

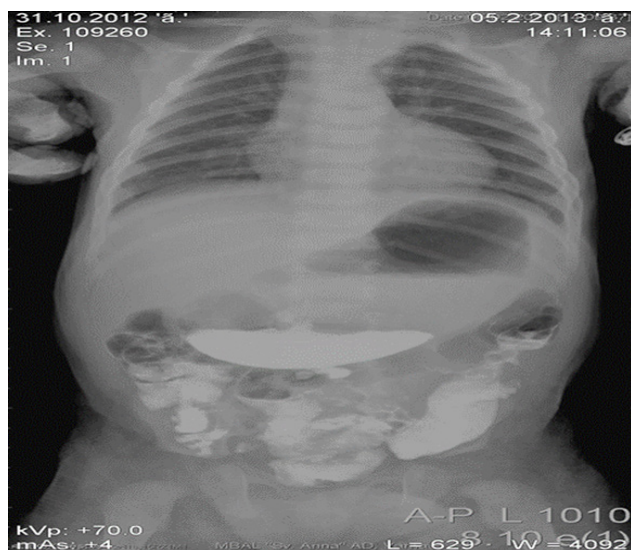

Figure 1. X-ray of the dilated stomach with the presence of contrast material from the previous examination.

The results of the laboratory tests showed WBC- $13.7 \times 10^9/L$; RBC- $3.94 \times 10^{12}/L$ with low hemoglobin and hematocrit of 114 g/L and 31% respectively. C-reactive protein levels were within normal limits - 3.1 mg/L. The coagulation profile was normal as well. The electrolyte panel indicated a sodium level of 139 mmol/L, chloride of 100 mmol/L and potassium of 3.8 mmol/L. pH -7.51, lactate -1.6 and Base excess -2.8. Total serum protein was 56.2 g/L, albumin was 42.4 g/L. Blood urea nitrogen -2.51 mmol/L; creatinine-28 mmol/L, AST was 49 U/L, ALT-37 U/L. The plain radiograph of the abdomen confirmed

the presence of contrast material in the stomach from the previous examination conducted in the children's department. The stomach was dilated at the level of L4-L5. There was also a contrast material in the large intestine, without formed hydroaeric levels (Figure 1).

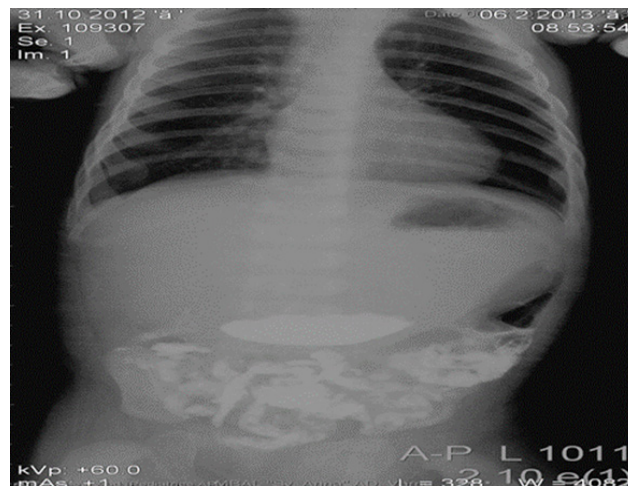


Figure 2. The contrast material depot persisted comparatively to the result of the previous X-ray.

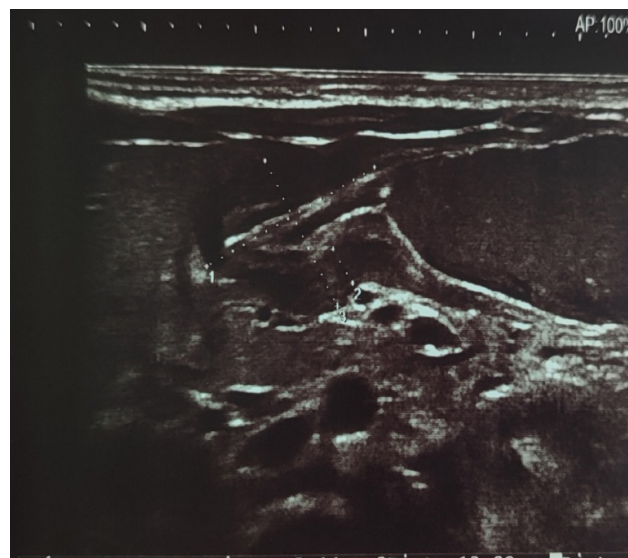


Figure 3. Ultrasound image of pyloric stenosis.

The plain radiograph of the abdomen the next day showed that the contrast material depot persisted comparatively to the result of the previous day. The presence of contrast material was also found in the small intestine (Figure 2). Abdominal ultrasound showed thickening of the gastric pyloric musculature. Pylorus length 18 mm and diameter 8 mm with circular muscle having thickness of 3.8 mm (Figure 3). After stabilization of the common condition and correction of the metabolic and electrolyte

disturbances, with half saline and glucose 5% and human albumin, the control abdominal radiographs confirmed the presence of two hydroaeric levels, one of which was from contrasting material and stayed more than 48 hours. After a long discussion, with clear data for difficult gastric evacuation, with a hypothetical diagnosis of duodenal stenosis and/or pyloric stenosis, it was decided to proceed with surgical treatment.

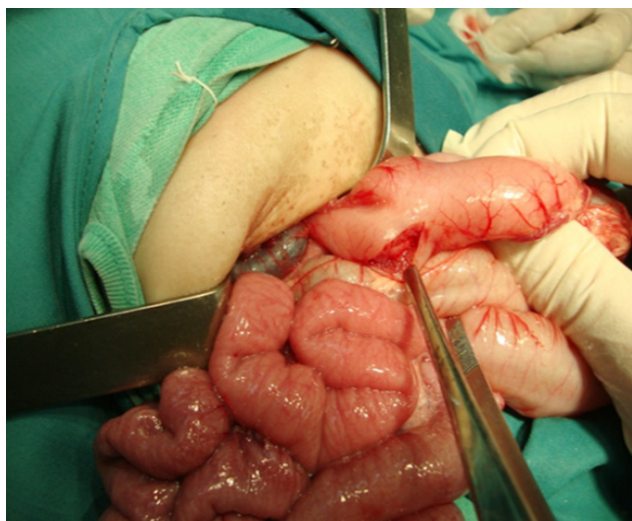

Figure 4. Fredet-Ramstedt pyloromyotomy.

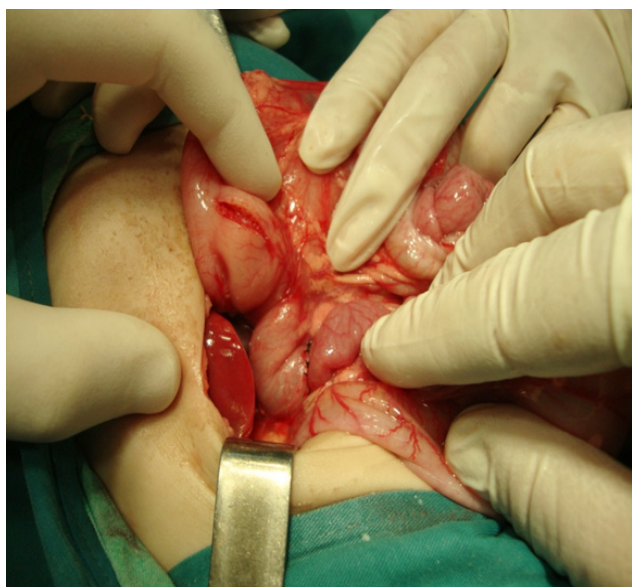

Figure 5. A latero-lateral duodeno-duodenal anastomosis.

Intraoperative findings

Under general anesthesia, a supraumbilical transverse laparotomy was performed. Intraoperative findings revealed a severely dilated stomach and hypertrophic pyloric stenosis. The length of the pylorus

was 1.5 cm. A Fredet-Ramstedt pyloromyotomy was also performed (Figure 4). The thickness of the pyloric wall was 6 mm. After the revision of the duodenum, dilation of the first and second parts of the duodenum was found. The dilated duodenum narrowed sharply at the point where the superior mesenteric artery passed the third part of the duodenum. A duodenotomy was performed and the stenotic portion from above and below was carefully and thoroughly checked. Our surgical approach was a two-layer latero-lateral duodeno-duodenal anastomosis using interrupted 4-0 suture (Figure 5). The abdominal cavity was also revised, and a surgical drain was placed in the anastomosis area. Postoperative care included infusions of glucose and electrolytes saline. Intravenous infusion was continued along with parenteral feeding, antibiotics (Amoxicillin/Clavulanic acid dose was 25 mg/kg/dose 8 hours and Metronidazole 20 mg/dose 8 hours), Immunovenin (3 ampoules daily for three consecutive days) and Famotidine (2x2 mg per day). Enteral feeding began the third day after surgery, and breastfeeding started without vomiting. The patient started to gain weight and was discharged on the sixth postoperative day with a weight of 3640 g.

Discussion

IHPS is one of the most common neonatal abdominal surgeries and is usually diagnosed between 3 and 5 weeks of age and occurs very rarely after 12 weeks of age [8].

Postprandial vomiting is the most important symptom in a patient with IHPS and progresses to projectile and relapsing. Recurrent vomiting and dehydration can cause electrolyte disturbances such as hypochloremic alkalosis, weight loss, and lethargy [9]. In 33.3% of IHPS cases, the classic olive-shaped mass is present in the abdomen of the patient, but in two-thirds of the cases the olive-shaped mass is not found [6,7]. The optimal treatment for infantile hypertrophic pyloric stenosis (IHPS) is the Fredet-Ramstedt extramucosal pyloromyotomy, which is considered the gold standard procedure.

On the other hand, Wilkie's syndrome is characterized by a narrowing of the aortomesenteric angle. In the physiological state and due to upright position, the angle of the aorta-SMA ranges from 38 to 65° [10,11] and is supported by the presence of perivascular adipose tissue.

Regarding the normal aortomesenteric distance, it is between 10 and 28 mm. In SMAS, the angle decreases dramatically in the range of 6° to 16°, as well as the distance, which can be shortened to 2 mm, resulting in extraluminal compression of the duodenum [10]. The etiological aspect of the disease is related to compression of the third portion of the duodenum between the abdominal aorta and the superior mesenteric artery, leading to duodenal obstruction and severe malnutrition. Etiological factors can be congenital or acquired. Congenital causes include abnormally short or high insertion of the ligament of Treitz, cranial displacement

of the duodenum, low insertion of the superior mesenteric artery (SMA), or peritoneal adhesions [12]. Acquired factors may result from various conditions. Catabolic states such as tumors, burns, and diseases causing severe weight loss, such as anorexia nervosa or malabsorption syndrome, are cited as potential causes. Severe cranial or spinal trauma, esophagectomies, or abdominal aortic aneurysms are associated with prolonged periods of immobilization, which is identified as a factor for the development of SMA syndrome [12]. Any condition leading to rapid weight loss results in the reduction of the fat cushion around the SMA and exacerbates the aortomesenteric angle [3].

Significant diagnostic information is obtained from abdominal imaging studies, including abdominal ultrasound, CT scan, and MRI [13,14]. Very few cases of superior mesenteric artery syndrome (SMAS) have been documented in infancy, with only 2 cases involving the neonatal period. The patients were female with symptoms of bilious vomiting and incomplete intestinal obstruction shortly after birth [15-18]. SMAS is quite unusual in early childhood and even rarer during the neonatal period, typically presenting acutely as incomplete intestinal obstruction and feeding intolerance. This can pose a diagnostic dilemma compared to more commonly associated causes of upper intestinal obstruction such as intestinal malrotation, duodenal stenosis or annular pancreas [19-22]. Selami et al. described diagnostic difficulties due to concurrent gastroenteritis in the patient, followed by a sepsis-like presentation, which can obscure the true mechanical obstruction caused by SMAS [15].

The syndrome is primarily characterized by postprandial epigastric pain, vomiting, malnutrition, significant weight loss, and anorexia. Wilkie's syndrome symptoms may present as acute obstruction of the upper gastrointestinal tract or more commonly, as a chronic presentation with unusual symptoms such as intermittent postprandial epigastric pain, nausea, vomiting with bile or food contents (sometimes in a fountain), early satiety, gastric dilatation, gastroesophageal reflux, regurgitation, and weight loss [12]. These symptoms may appear at a later age and go unrecognized.

The overlap of nonspecific symptoms makes it difficult to diagnose the two diseases. In our case, reported here, we note that during a careful revision of the upper gastrointestinal tract, we found a concomitant pathology that could have been missed. In the future, this would lead to the continuation of complaints and the need for a repeated surgical intervention to remove it. We also note the disadvantage of absence of angiograph in our hospital, which would be useful for a preliminary diagnosis of Wilkie's syndrome. Long-term experience in the treatment of congenital diseases empirically proves that "a malformation never comes alone". Therefore, in patients with congenital malformations of the gastrointestinal tract (GIT), we recommend a targeted search for concomitant

diseases, both from the GIT side and from other organs and systems. This contributes to the timely detection and treatment of both the main disease and accompanying conditions.

The authors of this article are convinced that within one surgery of a patient diagnosed with IHPS and SMAS, the results are more beneficial for the patient. The benefits can be summarized as: a faster recovery time to normal gastrointestinal motility and relief of emesis; a shorter length of stay and elimination of the possibility of the second operation. The consideration of a two-stage procedure would have been more complicated in this case due to the potential formation of additional adhesions and the impossibility of complete enteral nutrition [23]. This is the first reported case of a combination of pyloric stenosis with Wilkie's syndrome.

Conclusion

In conclusion, the surgical treatment with pyloromyotomy and duodenal-duodenal anastomosis within one operation is an optimal option for one-stage treatment of patients with IHPS and Wilkie's syndrome.

References

1. Lorentziadis ML. Wilke's syndrome. A rare cause of duodenal obstruction. *Ann Gastroenterol*. 2011;24:59-61.
2. Silva E, Ribiro C, Guerreiro S, Domingues A. Síndrome de Wilkie - a propósito de um caso clínico. *Revista Portuguesa de Cirurgia*. 2016;37:25-28. [Portuguese] Available from: <https://revista.spcir.com/index.php/spcir/article/view/420>
3. Claro M, Sousa D, Abreu da Silva A, Grilo J, Martins JA. Wilkie's Syndrome: An Unexpected Finding. *Cureus*. 2021;13:e20413.
4. Felton BM, White JM, Racine MA. An uncommon case of abdominal pain: superior mesenteric artery syndrome. *West J Emerg Med*. 2012;13:501-502.
5. Salem A, Al Ozaibi L, Nassif SMM, Osman RAGS, Al Abed NM, Badri FM. Superior mesenteric artery syndrome: A diagnosis to be kept in mind (Case report and literature review). *Int J Surg Case Rep*. 2017;34:84-86.
6. Schwartz MZ. Hypertrophic pyloric stenosis. In: Grosfeld JL, O'Neill JA, Fonkalsrud E, editors. *Pediatric Surgery*. 6. Philadelphia: Mosby - Elsevier. 2006, p. 1215-1223.
7. Al-Ghazwany S, Wahid FN, Al-Mohaidly M, Onanzi MA, Suliman A, Rawaf AA, et al. Infantile hypertrophic pyloric stenosis: a single institution's experience. *Ann Pediatr Surg*. 2012;8:39-41.
8. Son SK, Park JH, Choi BH, Choi KH, Lee KH. A clinical analysis of neonatal surgical gastrointestinal diseases in Daegu Busan area. *Korean J Pediatr Gastroenterol Nutr*. 2004;7:179-185.
9. Choi KJ. Infantile hypertrophic pyloric stenosis. *Ewha Med J*. 2012;35:16-20.

10. Bin Waqar SH, Khan AA, Mohiuddin O. Perplexing Case of Wilkie's Syndrome: A Rare Presentation in a Young Patient. *Cureus*. 2019;11:e5085.
11. Osegueda de Rodríguez EJ, Hernández-Villegas AC, Serralde-Zúñiga AE, Reyes-Ramírez ALDC. The two sides of superior mesenteric artery syndrome treatment: conservative or surgical management? *Nutr Hosp*. 2017;34:997–1000.
12. Marinho A. Medicina da Universidade de Lisboa. Faculdade de Medicina Universidade de Lisboa; 2015. Síndrome de Wilkie: Caso clínico. [Portuguese]
13. El Yousfi Z, Halfi IM, El Houss S, Allali N, El Haddad S, Chat L. Superior Mesenteric Artery Syndrome: A Misdiagnosed Disorder. *Glob Pediatr Health*. 2024;11:2333794X231221705.
14. Aldagher A, Almasri R, Mahmoud J. Superior mesenteric artery syndrome in an 8-year-old boy: a case report. *J Med Case Rep*. 2023;17:343.
15. Sözübir S, Kahraman H, Arslan A, Ekingen G, Güvenç BH. Incomplete duodenal obstruction in a newborn. *Indian J Pediatr*. 2006;73:364-366.
16. Caspi B, Deutsch H, Grunshpan M, Flidel O, Hagay Z, Appelman Z. Prenatal manifestation of superior mesenteric artery syndrome. *Prenat Diag*. 2003;23:932-934.
17. Burrington DJ, Wayne ER. Obstruction of the duodenum by the superior mesenteric artery--does it exist in children? *J Pediatr Surg*. 1974;9:733-741.
18. Okugawa Y, Inoue M, Uchida K, Kawamoto A, Koike Y, Yasuda H, et al. Superior mesenteric artery syndrome in an infant: case report and literature review. *J Pediatr Surg*. 2007;42:E5-E8.
19. Shi Y, Shi G, Li Z, Chen Y, Tang S, Huang W. Superior mesenteric artery syndrome coexists with Nutcracker syndrome in a female: a case report. *BMC Gastroenterol*. 2019;19:15.
20. Nunn R, Henry J, Slessor AA, Fernando R, Behar N. A Model Example: Coexisting Superior Mesenteric Artery Syndrome and the Nutcracker Phenomenon. *Case Rep Surg*. 2015;2015:649469.
21. Schwarz J, Sýkora J, Pomahačová R, Sýkorová A, Fremuth J, Šašek L, et al. Rare cause of upper bowel obstruction arising in a 17-year-old boy with cystic fibrosis: Superior mesenteric artery (Wilkie's) syndrome. *J Paediatr Child Health*. 2020;56:1827-1829.
22. Lin TH, Lin CC, Tsai JD. Superior mesenteric artery syndrome and nutcracker syndrome. *Pediatr Neonatol*. 2020;61:351–352.
23. Fruchter S, Marshall J, Alexander F. Two birds, one surgical stone: The first reported case of superior mesenteric artery syndrome secondary to biliary dyskinesia. *Journal of Pediatric Surgery Case Reports*. 2016;12:38-40.