



A case of multi-plug flow control technique treating high flow cirroid renal arteriovenous malformations

Emre Can Çelebioğlu¹, Aysegul Coruh Gursoy², Matheus Dabus³, Sadık Bilgiç¹

1) Department of Radiology / Vascular Interventional Radiology, Faculty of Medicine, Ankara University, Ankara, Turkey

2) Department of Radiology, Faculty of Medicine, Ankara University, Ankara, Turkey

3) Baptist Health Miami Cardiac & Vascular Institute, Miami-FL, USA

Abstract

Introduction. Renal arteriovenous malformations (AVMs) are rare vascular lesions mostly diagnosed when they become symptomatic. These lesions can be treated using a variety of endovascular techniques and devices.

Case Report. We present a 51-year-old male who presented with acute onset right flank pain, hematuria and refractory hypertension. The patient was treated using a multi-plug flow control technique using multiple balloon catheters and microcatheters. Two operators worked synchronously during the procedure using two different dilutions of glue. The patient's symptoms resolved immediately after the embolization and at 1 month follow up the CT demonstrated complete obliteration of the AVM with little renal parenchymal loss. The patient remained clinically asymptomatic at the 6-months follow-up.

Conclusion. This case illustrates the feasibility and safety use of synchronous embolization in the treatment of complex renal AVMs.

Keywords: renal arteriovenous malformation, kidney diseases, embolization, liquid embolic agent

Introduction

Renal arteriovenous malformations (AVMs) are very rare and they are complex vascular lesions occurring in less than 1% of the general population. Many different classification systems were used for the classification of these complex lesions and classically they have been classified in three different forms: cirroid, aneurysmal and angiomatous types [1,2]. Cirroid or Type 3 AVMs are the most frequent form of these vascular lesions composed of multiple arterial and venous shunts, making their treatment rather complex [1,2].

When found incidentally, these lesions are usually monitored until they become symptomatic. Conversely, patients with clinical symptoms such as gross hematuria, retroperitoneal hemorrhage, flank pain, refractory hypertension or high-output heart failure require treatment, which is at times

lifesaving [1,3]. Surgical nephrectomy, risking the patient's renal function, is the surgical option. On the other hand, in situations where renal function needs to be preserved, endovascular embolization techniques are the preferred treatment strategies [1-5]. Different complex approaches have been described in the literature usually in the form of small case series and case reports [6-8].

In this report we present a case of symptomatic renal cirroid AVM treated successfully with embolization using a multi-plug flow control technique resulting in angiographic cure.

Case Report

A 51-year-old male patient presented with acute onset of flank pain, hypertension and hematuria to an outpatient institution. An abdominal ultrasound revealed right renal hypervascular lesion and AVM was

DOI: 10.15386/mpr-2769

Manuscript received: 12.07.2024

Received in revised form: 19.10.2024

Accepted: 07.11.2024

Address for correspondence:
Emre Can Çelebioğlu
emrecelebioглу@yahoo.com.tr

This work is licensed under a Creative Commons Attribution-NonCommercial-NoDerivatives 4.0 International License <https://creativecommons.org/licenses/by-nc-nd/4.0/>

Case Report

diagnosed by computed tomography. The patient was then referred to our institution's interventional radiology clinic. A diagnostic digital subtraction angiography (DSA) was performed to better evaluate the AVM's angio-architecture and, if possible, treat it in the same session.

The patient was positioned in supine position during the procedure and both femoral regions were prepped and draped in the usual sterile fashion. The right femoral artery was punctured first and a 6 Fr sheath (Terumo Corp., Tokyo, Japan) was placed. The diagnostic DSA demonstrated

a high flow cirroid AVM supplied by two renal arteries separately with enlarged renal veins (Figure 1). The left femoral artery was also punctured and a 45 cm 6Fr long sheath was advanced to the superior and larger renal artery. Following that, a 6 Fr renal double curved guiding catheter (RDC II, Boston scientific, USA) was advanced and positioned at the ostium of the smaller arterial branch. Diagnostic angiographic images with higher frame rates (7-9 fps) were then obtained to further understand the AVM's morphology.

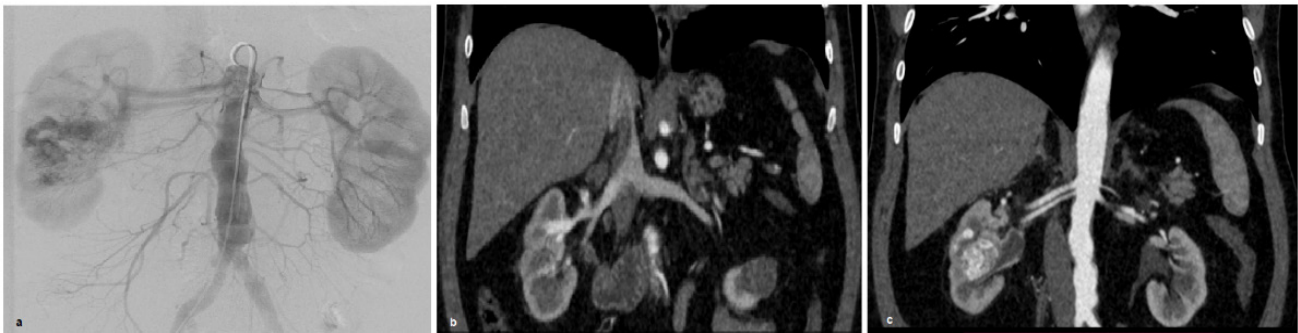

Figure 1. DSA and CT images obtained prior to treatment. **1a.** DSA images obtained prior to endovascular embolization. **1b. and 1c.** CT images obtained prior to treatment demonstrates enlarged renal veins and double renal arteries.

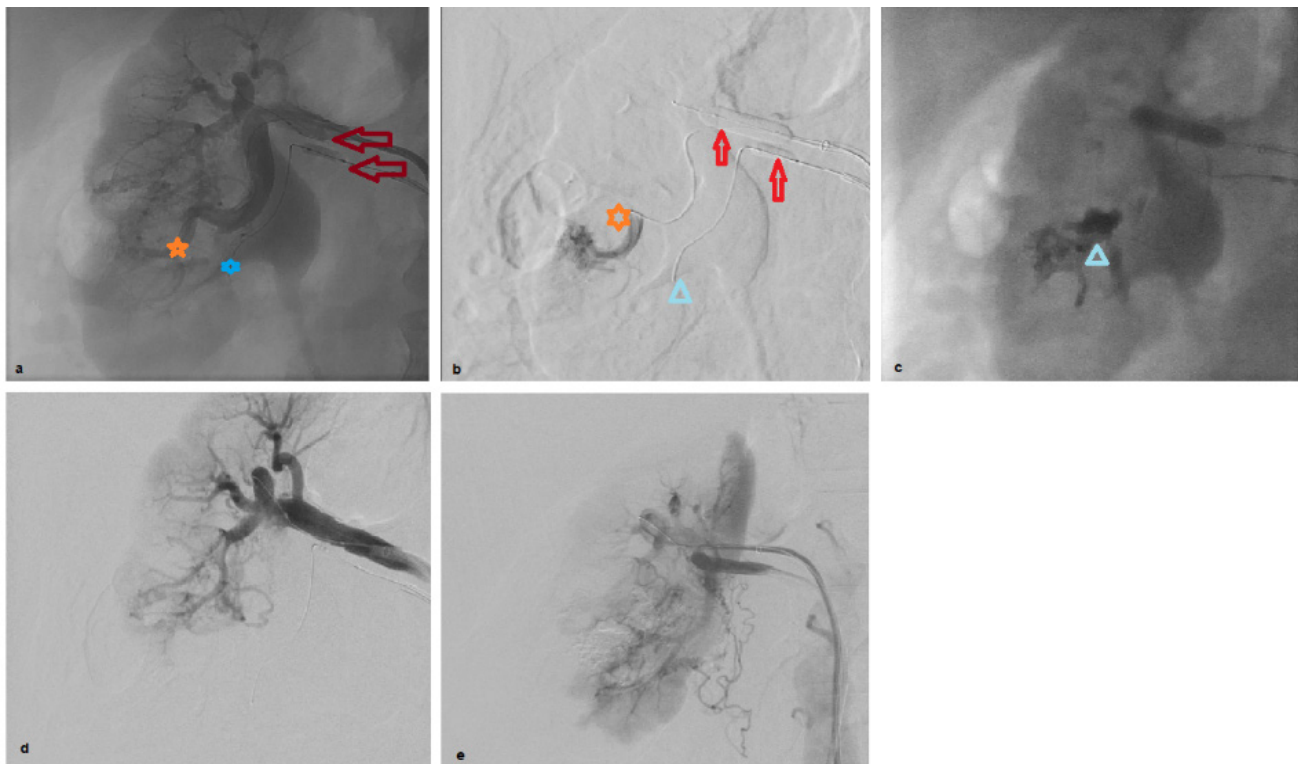


Figure 2. DSA images during endovascular embolization. **2a.** Both renal arteries were catheterized and microcatheters (orange and blue stars) were inserted distally to the balloons (red arrows). **2b.** Glue injection through microcatheters (star and triangle) during double balloon occlusion (red arrows). **2c.** Glue cast after embolizations (blue triangle). **2d. and 2e.** DSA images obtained initially after embolizations shows cured avm.

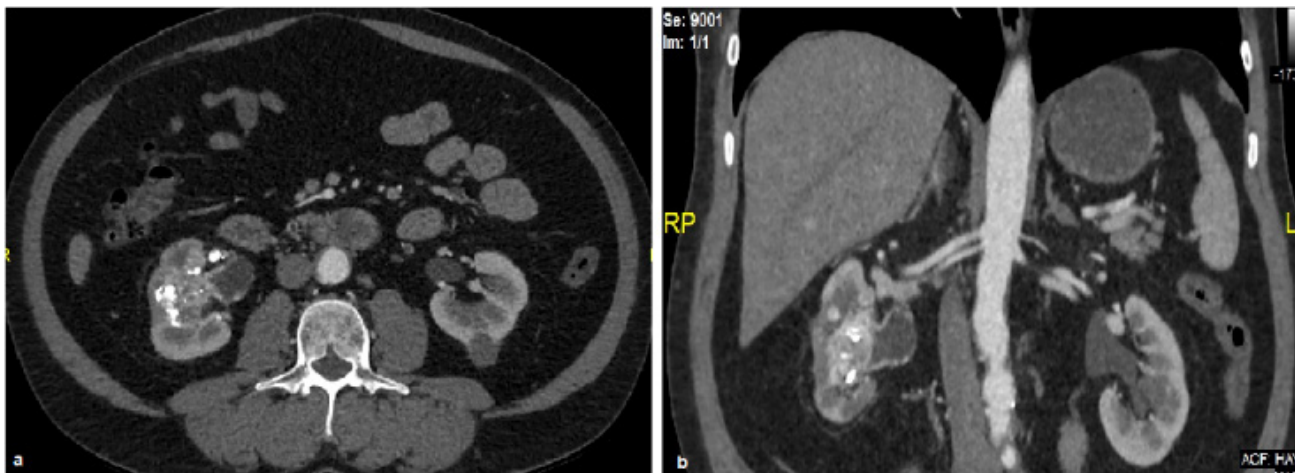

Figure 3. Axial and coronal images obtained at one month control. **3a. and 3b.** Cured renal AVM with minimal parenchymal loss was demonstrated at the control imaging.

Because of the high flow, balloons were used in the arterial feeders to decrease the flow and decision was made to proceed with selective liquid embolizing agent *n-Butyl cyanoacrylate* (NBCA) (Histoacryl, B.Braun, Germany), embolization protecting the patient's renal parenchyma and preventing a systemic venous glue embolization. Therefore, an NBCA-compatible 1.9 Fr microcatheter (Carnelian, Tokai Medical Products Inc., Japan) was advanced ultraselectively to the farthest segment of the nidal portion coaxially through the guiding catheter while a 3 x 20 mm monorail balloon (Sterling, Boston scientific, USA) was inflated at the proximal portion of the smaller renal arterial branch. Next, another NBCA compatible 2.2 Fr microcatheter (Carnelian, Tokai Medical Products Inc., Japan) was advanced to the main feeder of the AVM coaxially through the 6Fr sheath alongside a larger monorail balloon catheter (5x20mm, Sterling, Boston Scientific, USA). Subsequently, a couple of test injections with iodinated contrast (Iohexol 350 mg I/ml, Omnipaque, Norway) were done through microcatheters with different variations of balloon occlusion inflation. Finally, two different glue dilutions (1:3, 1:6) were used through each microcatheters simultaneously using a multi-plug flow control technique under balloon occlusion (Figure 2). During the simultaneous embolization, each operator was responsible for one balloon and microcatheter combination, treating the patient as a team and communicating with each other continuously for a controlled and precise treatment.

The final DSA images performed after the embolization demonstrated the occlusion of AVM with minimal renal parenchymal deficit. The patient was discharged from hospital the same day. The patients' hematuria, flank pain and refractory hypertension

resolved immediately after embolization. A follow up CTA performed 1 month after the treatment demonstrated complete occlusion of the AVM (Figure 3). The patient was still symptom-free in the 6-months clinical follow up.

Discussion

AVMs are complex lesions and their treatments should be performed by experienced operators for best results benefitting the patients. Depending on the location, surgery can be a good option for some of these AVMs. Renal AVMs can indeed be treated by surgical resection; however, most of the cases would require nephrectomy risking the patient's renal function. Therefore, endovascular embolization is the preferred first line treatment for symptomatic renal AVMs.

Although the numbers of incidentally found renal AVMs is increasing due to the growing numbers of the screening imaging, its prevalence is still very low 0.04% [9]. Asymptomatic patients with renal AVMs are usually managed conservatively with follow up whereas symptomatic patients are usually treated [10]. Although multislice imaging with CT has improved the diagnostic rates, the gold standard diagnostic modality is DSA images which demonstrates the anatomy of the lesion dynamically with the ability of high frame imaging [1]. Furthermore, operators can treat the patients at the same session after the diagnostic DSA in emergent settings or do a more detailed imaging for an elective session [1-3]. 4D imaging is another great option enhancing the results by helping to understand the anatomy and morphology for these complex AVMs [11,12].

Arteriovenous malformations and fistulas in different body localizations have been treated either preoperatively before a definitive surgical operation or

curatively in single/multiple sessions [13,14]. Dabus et al. and other authors have described their results using different catheter systems with different embolizing agents such as coils, particles, and liquid embolics treating these complex lesions all over the body segments [15]. Trans-arterial, direct percutaneous and trans-venous embolizations have been described by numerous other authors [7,8,13,14]. We prefer to treat this high flow lesion via multiple arterial accesses successfully using NBCA glue with two different dilutions.

Implementing a treatment plan for peripheral interventions using lessons learned from other areas such as interventional neuroradiology can raise the chance of success. There are several publications demonstrating devices and techniques originally described for the neurointerventions being successfully employed in the treatment of peripheral [16-18]. Nowadays, there is a higher percentage of curative treatment of the brain arteriovenous malformations and fistulas mostly due to the newer and better devices. 'Pressure cooker technique' and 'Team Limoges Technique' are the well-known and some of the most sophisticated techniques for brain AVMs treatment [19]. Cekirge et al. recently described a modified new technique treating brain AVMs with liquid embolizing agent, using multiple microcatheters through multiple different arterial feeders [20]. Therefore, we used this knowledge for the treatment of this patient resulting in complete occlusion of this complex renal AVM without complications.

In **conclusion**, renal arteriovenous malformations can be successfully treated with the multi-plug flow control technique. Flow control is the most important step allowing slow, progressive and controlled injection of the embolic agent into the AVM shunts preserving most of the renal parenchyma. This case also demonstrates the importance of cross-functional teamwork in the planning and execution of treatment for these complex lesions.

References

1. Choi SK, Min GE, Lee DG. Congenital renal arteriovenous malformation: diagnostic clues and methods. *Medicina (Kaunas)*. 2021;57:1304.
2. Hayashi H, Kiyosue H, Tamura Y, Ueda H, Yonemura M, Sasaki G, et al. Transarterial embolization of renal arteriovenous malformations: treatment outcomes according to angiographic classification. *J Vasc Interv Radiol*. 2024;35:979-988.e1.
3. Takebayashi S, Hosaka M, Kubota Y, Ishizuka E, Iwasaki A, Matsubara S. Transarterial embolization and ablation of renal arteriovenous malformations: efficacy and damages in 30 patients with long-term followup. *J Urol*. 1998;159:696-701.
4. Somani BK, Nabi G, Thorpe P, Hussey J, McClinton S. Therapeutic transarterial embolisation in the management of benign and malignant renal conditions. *Surgeon*. 2006;4:348-352.
5. Hwang JH, Do YS, Park KB, Chung HH, Park HS, Hyun D. Embolization of congenital renal arteriovenous malformations using ethanol and coil depending on angiographic types. *J Vasc Interv Radiol*. 2017;28:64-70. doi: 10.1016/j.jvir.2016.09.004. Epub 2016 Nov 16. Erratum in: *J Vasc Interv Radiol*. 2017;28:775. doi: 10.1016/j.jvir.2017.03.006.
6. Lee SY, Do YS, Kim CW, Park KB, Kim YH, Cho YJ. Efficacy and Safety of Transvenous Embolization of Type II Renal Arteriovenous Malformations with Coils. *J Vasc Interv Radiol*. 2019;30:807-812.
7. Uchikawa Y, Mori K, Shiigai M, Konishi T, Hoshiai S, Ishigro T, et al. Double coaxial microcatheter technique for glue embolization of renal arteriovenous malformations. *Cardiovasc Intervent Radiol*. 2015;38:1277-1283.
8. Ffrench-Constant S, Weerakoon N, Amin R, Dixon L, Taube D, Hamady M. Dual-balloon assisted super-selective embolisation of high flow arterial venous fistula within a transplant kidney. *CVIR Endovasc*. 2018;1:21.
9. Balasubramanian K, Keshava SN, Lenin A, Mukha R. Endovascular management of a patient with massive renal arteriovenous fistula: challenges and tricks. *BMJ Case Rep*. 2021;14:e236358.
10. Jia ZY, Zhou CG, Xia JG, Zhao LB, Zhang W, Liu S, et al. Endovascular treatment of 12 cases of renal arteriovenous malformations: the experience of 1 center and an overview of the literature. *Vasc Endovascular Surg*. 2018 ;52:46-51.
11. Ruedinger KL, Schafer S, Speidel MA, Strother CM. 4D-DSA: Development and current neurovascular applications. *AJNR Am J Neuroradiol*. 2021;42:214-220.
12. Lang S, Göllitz P, Struffert T, Rösch J, Rössler K, Kowarschik M, et al. 4D DSA for dynamic visualization of cerebral vasculature: a single-center experience in 26 cases. *AJNR Am J Neuroradiol*. 2017;38:1169-1176.
13. Gegenava BB, Shumakov DV, Osiev AG, Chukumov RM, Bavykin AA. Retrograde transvenous balloon-assisted Onyx embolization of mandibular arteriovenous malformation after hemorrhage. *Radiol Case Rep*. 2018;14:348-353.
14. Rose SC, Berman ZT, Fischman AM, Young LB, Flanagan S, Katz MD, et al. Inline balloon occlusion-assisted delivery of ethylene vinyl alcohol copolymer for peripheral arterial applications: a multicenter case series. *J Vasc Interv Radiol*. 2020;31:986-992.
15. Dabus G, Linfante I, Benenati J, Perlyn CA, Martínez-Galdámez M. Interventional management of high-flow craniofacial vascular malformations: a database analysis and review of the literature. *J Neurointerv Surg*. 2017;9:92-96.
16. Murray TÉ, Brennan P, Maingard JT, Chandra RV, Little DM, Brooks DM, et al. Treatment of visceral artery aneurysms using novel neurointerventional devices and techniques. *J Vasc Interv Radiol*. 2019;30:1407-1417.
17. Akkan K, Ilgit E, Karaman K, Onal B, Dökdök M, Ersöz E,

- et al. The new double-layer micromesh stent (Roadsaver®): use in endovascular treatment of supraaortic and visceral artery aneurysms and pseudoaneurysms. *Cardiovasc Intervent Radiol.* 2017;40:1338-1343.
18. Das JP, Asadi H, Kok HK, Phelan E, O'Hare A, Lee MJ. Balloon-assisted coil embolization (BACE) of a wide-necked renal artery aneurysm using the intracranial scepter C compliant occlusion balloon catheter. *CVIR Endovasc.* 2018;1:12.
 19. Batista S, Almeida Filho JA, Oliveira LB, Koester S, Pinheiro AC, Dinato RA, et al. Evaluating the safety and efficacy of transvenous embolization for brain arteriovenous malformation: A systematic review and meta-analysis. *Interv Neuroradiol.* 2023;15910199231204922.
 20. Cekirge HS, Saatci I. Republished: Multiplug flow control technique as a novel transarterial curative approach for the endovascular treatment of cerebrovascular malformations. *J Neurointerv Surg.* 2023;15:e4.