



Clinical and ultrasonographic evaluation of breast lipofilling after expander extrusion. Case report

Razvan-George Bogdan¹, Alina Helgiu², Anca-Maria Cimpean^{1,3}, Zorin Petrisor Crainiceanu^{1,3}

1) Plastic Surgery Department, "Victor Babes" University of Medicine and Pharmacy, Timisoara, Romania

2) Emergency County Clinical Hospital, Sibiu, Romania

3) Pius Branzau Emergency County Clinical Hospital, Timisoara, Romania

Abstract

Background. Breast cancer treatment often involves mastectomy and adjuvant therapies such as radiotherapy, which can lead to complications in reconstructive procedures. Tissue expanders are commonly used for immediate breast reconstruction post-mastectomy, but radiation therapy increases the risk of complications like expander extrusion. Lipofilling has emerged as a promising technique to address tissue damage and improve reconstructive outcomes. This case illustrates the utility of ultrasonography in measuring fat thickness before and after the lipofilling procedure and calculating the resorption rate for managing complex post-radiation complications.

Case description. We report the case of a 38-year-old patient born and raised in Romania with a history of right breast cancer, who initially underwent mastectomy followed by immediate reconstruction with a subpectoral tissue expander. The patient subsequently received adjuvant radiotherapy, which led to the extrusion of the tissue expander and chronic pain with skin redness. Due to significant damage to the surrounding tissue and chest wall, lipofilling was employed as a reconstructive approach to enhance skin quality and support tissue regeneration. Fat grafting was performed in multiple sessions, with ultrasonographic evaluations conducted before and after each session to monitor volumetric changes in the reconstructed breast. Following lipofilling, the patient experienced marked improvements in skin texture and breast volume, with no recurrence of complications. Later that year we performed a DIEP flap.

Conclusions. This case demonstrates the efficacy of ultrasonography in measuring fat graft and fat resorption after lipofilling as a reconstructive strategy in patients who experience complications from tissue expander extrusion post-radiation. Lipofilling, in combination with thorough imaging assessments, can significantly enhance the outcomes of breast reconstruction following radiotherapy.

Keywords: breast neoplasms, mastectomy, lipofilling, tissue expansion devices, radiotherapy, ultrasonography

DOI: 10.15386/mpr-2826

Manuscript received: 16.10.2024

Received in revised form: 30.10.2024

Accepted: 20.11.2024

Address for correspondence:

Razvan-George Bogdan
razvan.bogdan@umft.ro

This work is licensed under a Creative Commons Attribution-NonCommercial-NoDerivatives 4.0 International License <https://creativecommons.org/licenses/by-nc-nd/4.0/>

Introduction

Many researchers have focused on adipose tissue, which has been utilized for a long time as a filler in plastic and cosmetic surgery. The practice of autologous adipose transplantation was first noted toward the end of the 19th Century. Both concepts and approaches have undergone significant modification in the last century. In recent years, interest in adipocyte transplantation has been rekindled because of the description of Coleman's Lipostructure®, a novel technique based on a special substance and exacting approach. Theoretically, autologous fat transplantation offers the best remedy for soft tissue abnormalities [1].

Despite the introduction of fat grafts more than a century ago, numerous concerns and problems remain unresolved. The primary barriers to using fat grafts are the lack of certainty surrounding their outcomes and the need for fat development and retention to preserve graft volume [2].

With the containing adipose-derived stem cells, autologous fat grafting offers a reasonable option for managing scars by offering advantages in terms of appearance and functionality. Through cellular differentiation, extracellular matrix reshaping immune modulation, and angiogenesis, adipose-derived stem cells enhance wounded tissues. Autologous fat grafting is beneficial for a variety of scar disorders, including fibrosis, volume loss, and persistent discomfort. It also helps cure chronic wounds and lessen pathological scarring [3].

With ultrasound, subcutaneous fat thickness may be measured with accuracy and simplicity in a variety of test types, including abdominal, gynecological, and superficial soft tissue ultrasounds [4]. It has a reliability rate over 98% and is distinguished for its exceptional accuracy, repeatability, and sensitivity relative to alternative methods [5]. Prior to utilizing ultrasound to assess subcutaneous fat, no special preparation is required. Subcutaneous fat typically accounts for 40–60% of total body fat accumulation [6]. An 8-12 MHz linear array is used during ultrasonography examination to provide B-mode pictures, which are subsequently evaluated to ascertain the thickness of breast fat at various locations. This method is a mainstay in clinical examinations since it offers accurate and non-invasive measurements [7]. In addition, lipofilling can be utilized to improve skin quality and results from breast reconstruction with implants or autologous tissue [8–10].

We report a patient whose immediate tissue expander-based breast reconstruction resulted in late surgery site expander extrusion, which caused implant failure following radiation therapy. We performed a lipofilling session and evaluated clinically and by ultrasound the fat thickness before and after the procedure; based on the measurements we could approximate the fat resorption in the measured areas. Importantly, even in situations when there are large surgical scars, a series of surgical procedures can restore the patient's self-esteem.

We present this case in accordance with the CARE reporting checklist.

Case report

A 38-year-old woman (non-smoker, history of one pregnancy, one birth, abdominal diastasis, no relevant past interventions), with upper-outer quadrant right infiltrative breast carcinoma NST G2 ypT1miN1aL0V0R0 with mucinous components diagnosed through percutaneous biopsy, 1.8/1.5 cm in dimensions, hormone independent with HER-2 score: 3+, ER 40%, PR 50%, Ki-67: 52% with 8 cures of neoadjuvant chemotherapy done on April 2023 (opted for chemotherapy type 4*EC+4*PTX+Pertuz+Trastuz) and hormonal treatment (adjuvant with Gosereline 3.6 mg S. C/month 2y + Tamoxifen 20 mg/d - 5y) with no mutation identified on hereditary panel, underwent right breast radical modified mastectomy in May 2023 with axillary lymphadenectomy and immediate reconstruction with tissue expander (400 ml capacity) placed subpectorally in the "Pius Branzeu" Hospital, Casa Austria, Timisoara, Romania, Plastic Surgery department. The evolution of the patient was favorable and after surgical healing, she completed her radiotherapy (25 cures of each 2 Gy, 50 Gy total, finished on September 2023). In December 2023 she was admitted to our hospital with acute radiodermatitis with skin redness, moderate pain and spontaneous extrusion of tissue expander. The surgery to remove it was performed with no other significant clinical findings at physical examination with a favorable prognosis. In February 2024, after clinical and ultrasound evaluation (Figure 1 and 2), the redness and pain was still present and she underwent a lipofilling session. It was performed after proper preparation of the surgical field. Using about 150 ml of Klein solution being infiltrated in each abdominal flank, liposuction was performed with a Mercedes cannula, harvesting about 120 ml of fat. We prepared it by washing with saline solution 0.9% 200 ml 5 times. After each washing, we used the decantation method and injected in the subcutaneous tissue of interest of the right hemithorax. Immediate postoperatively, an echography was performed to measure the thickness of the subcutaneous tissue, and another clinical (Figure 3) and ultrasound evaluation was done in June 2024 (Figure 2). Postoperatively the patient received 5 days of unfractionated heparin 0.4 ml, one injection per day. There were no challenges in diagnosing. The results were as expected, both the surgeons and the patient were satisfied with the postoperative result. The patient adherence was as we expected, she was trustful and had a positive attitude. She tolerated the intervention with ease, the next day after the intervention she was discharged healthy with recommendations. There were no adverse or unanticipated events.

At ultrasound the probe was placed perpendicular in the same place in all examinations for the comparison between the three ultrasound exams to be accurate (Figure 4).

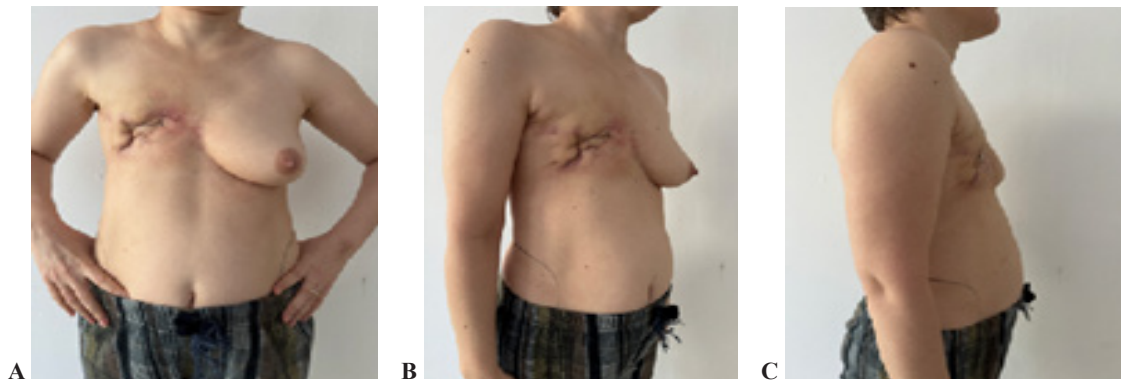


Figure 1. Patient before the lipofilling session (A-C from front view to lateral view).

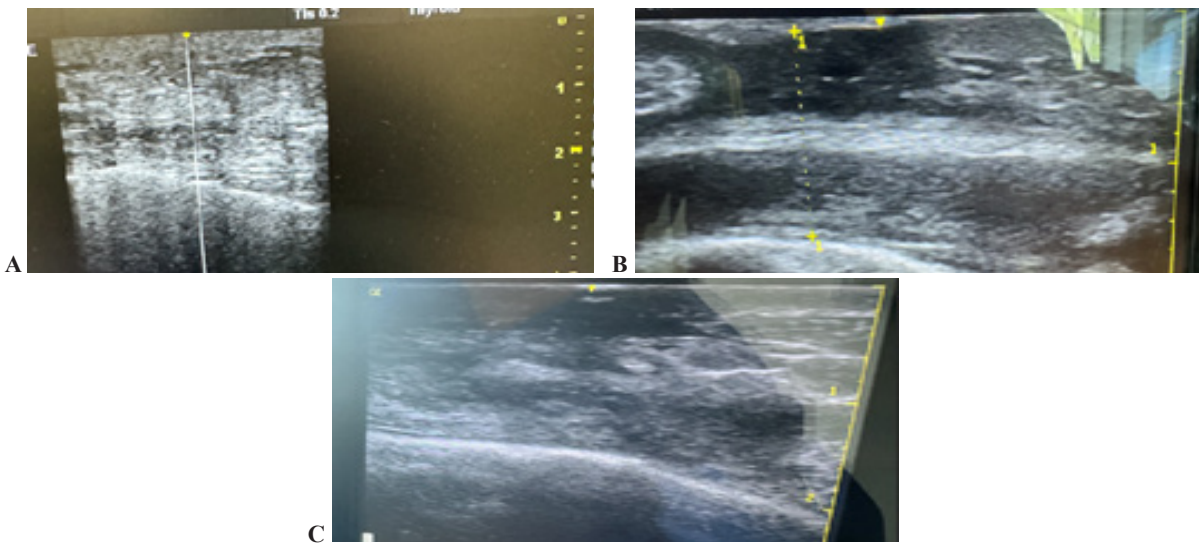


Figure 2. Ultrasonography evaluation (A. Before the lipofilling session; B. First day postoperative; C. 3 months after the operation).

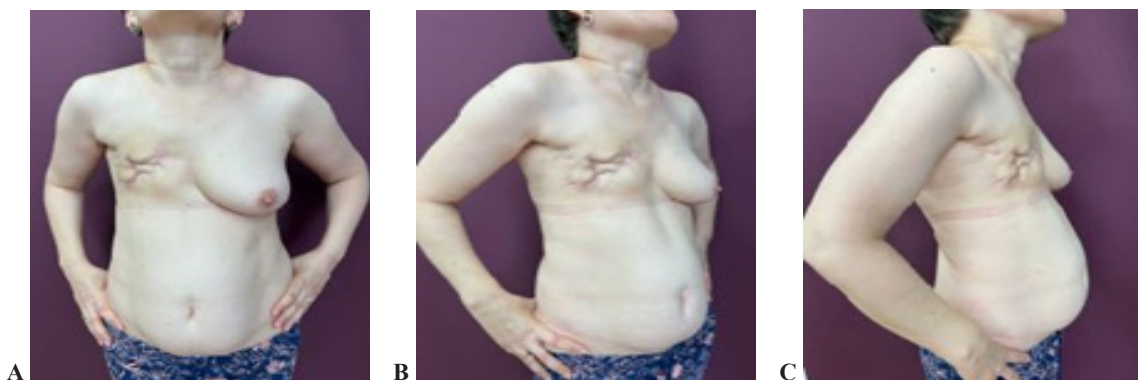

Figure 3. Patient 3 months after the lipofilling session A-C from front view to lateral view.

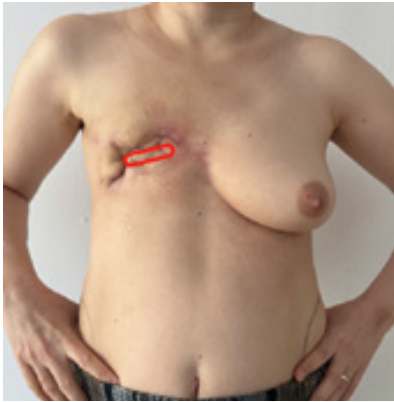

Figure 4. The position of the probe in all 3 examinations marked with red.

Discussion

Ultrasound evaluation after autologous fat transplantation does not mainly analyze volume retention but instead focuses on identifying problems [11]. Although ultrasound is a very reliable method, the gold standard for measuring adipose tissue volume remains magnetic resonance imaging [12].

We chose the same point of evaluation as in figure 4 in all 3 examinations; the volume retention can be approximated by the thickness differences between the evaluations. In the present case, the preoperative assessment reveals around 1 cm of subcutaneous tissue, 3 cm right after surgery, and roughly 2 cm after three months. So the retention volume is about 50-60 % in the evaluated area. This percentage does not mean that this result is the same in all other lipofilled areas.

The whole volume retention can also be assessed by analyzing longitudinal and transverse scans within the region of interest, ranging from the pectoral muscle fascia to the dermis, at intervals of one centimeter before and after the procedure [13].

Khouri et al. showed a greater complication rate and more treatments required in the event of prior radiation in one of the biggest series of breast lipofilling [13]. Skin sensitivity following fat injection-based breast restoration revealed less artificial values than following perforator flap reconstruction or expander-based procedures, as Heine et al. were able to show [14]. Debald et al.'s study included 26 patients who had radiation from a total of 40 people who had lipofilling treatments following breast surgery (23 patients with mastectomy, whereas 17 patients underwent breast conserving therapy after breast cancer diagnosis). Improvements in soft tissue and skin were observed following radiation therapy and lipofilling [15]. In the presented case, the redness subsided, the pain relieved, and the skin sensation markedly improved after the lipofilling session.

As a “takeaway” lesson from this case report, ultrasonography is a very useful tool, fast, efficient, and

cost-effective, with few limitations that can be used to measure the fat thickness and to calculate the reabsorption rate in small areas, although magnetic resonance imaging is still the gold standard for measuring the breast volume if lipofilling is performed by sector. The interested zone should be marked before the operation, and at the next examination, the probe must stay in the same position as the initial one, in order to prevent erroneous results.

Conclusions

Lipofilling can enhance soft tissue quality as an extra aid for reconstructing the breasts after mastectomy and radiotherapy [16].

Ultrasound can be a good tool to assess subcutaneous tissue thickness and can also be used to approximate the retention of the fat graft in interested areas if compared to preoperative imaging.

Funding

We would like to acknowledge Victor Babes University of Medicine and Pharmacy Timisoara for their support in covering the costs of publication for this research paper.

Ethical approval

This study was approved by the institutional Ethics Committee of the “Victor Babes” University of Medicine and Pharmacy, Timisoara, Romania and by the Pius Branzu Emergency County Clinical Hospital of Timisoara.

All procedures performed in studies involving human participants were in accordance with the ethical standards of the institutional research committee and with the 1964 Helsinki Declaration and its later amendments or comparable ethical standards.

Consent

The written consent on using the patient's photographic documentation and medical history for publication was obtained from the patient included in this study.

References

1. Mojallal A, Foyatier JL. Historical review of the use of adipose tissue transfer in plastic and reconstructive surgery. *Ann Chir Plast Esthet.* 2004;49:419-425. French.
2. Trojahn Kolle SF, Oliveri RS, Glovinski PV, Elberg JJ, Fischer-Nielsen A, Drzewiecki KT. Importance of mesenchymal stem cells in autologous fat grafting: a systematic review of existing studies. *J Plast Surg Hand Surg.* 2012;46:59-68.
3. Ahmad N, Anker A, Klein S, Dean J, Knoedler L, Remy K, et al. Autologous Fat Grafting-A Panacea for Scar Tissue Therapy? *Cells.* 2024;13:1384.

4. Störchle P, Müller W, Sengeis M, Ahammer H, Fürhapter-Rieger A, Bachl N, et al. Standardized Ultrasound Measurement of Subcutaneous Fat Patterning: High Reliability and Accuracy in Groups Ranging from Lean to Obese. *Ultrasound Med Biol.* 2017;43:427-438.
5. Smith-Ryan AE, Fultz SN, Melvin MN, Wingfield HL, Woessner MN. Reproducibility and validity of A-mode ultrasound for body composition measurement and classification in overweight and obese men and women. *PLoS One.* 2014;9:e91750.
6. Carpéné C, Les F, Hasnaoui M, Biron S, Marceau P, Richard D, et al. Anatomical distribution of primary amine oxidase activity in four adipose depots and plasma of severely obese women with or without a dysmetabolic profile. *J Physiol Biochem.* 2016;73:475-486.
7. Calabrese S, Zingaretti N, De Francesco F, Riccio M, De Biasio F, Massarut S, et al. Long-term impact of lipofilling in hybrid breast reconstruction: retrospective analysis of two cohorts. *Eur J Plast Surg.* 2020;43:257-268.
8. Uhlmann NR, Martins MM, Piato S. 3D areola dermopigmentation (nipple-areola complex). *Breast J.* 2019;25:1214-1221.
9. Visser NJ, Damen THC, Timman R, Hofer SOP, Mureau MAM. Surgical results, aesthetic outcome, and patient satisfaction after microsurgical autologous breast reconstruction following failed implant reconstruction. *Plast Reconstr Surg.* 2010;126:26-36.
10. Szymankiewicz M, Nowikiewicz T, Biedka M. Significance of Infections in Implant Loss After Breast Reconstruction in the Course of Breast Cancer Treatment. *Pol J Microbiol.* 2019;68:343-351.
11. Herold C, Ueberreiter K, Busche MN, Vogt PM. Autologous fat transplantation: volumetric tools for estimation of volume survival. A systematic review. *Aesthetic Plast Surg.* 2013;37:380-387.
12. Herly M, Müller FC, Ørholt M, Hansen J, Sværke S, Hemmingsen MN, et al. The current gold standard breast volumetry technique seems to overestimate fat graft volume retention in the breast: A validation study. *J Plast Reconstr Aesthet Surg.* 2019;72:1278-1284.
13. Khouri RK, Rigotti G, Khouri RK Jr, Cardoso E, Marchi A, Rotemberg SC, et al. Tissue-engineered breast reconstruction with Brava-assisted fat grafting: a 7-year, 488-patient, multicenter experience. *Plast Reconstr Surg.* 2015;135:643-658.
14. Heine N, Eigenberger A, Brebant V, Hoesl V, Brix E, Prantl L, et al. Comparison of skin sensitivity following breast reconstruction with three different techniques: Autologous fat grafting, DIEP flap and expander/implant. *Clin Hemorheol Microcirc.* 2022;80:389-397.
15. Debald M, Pech T, Kaiser C, Keyver-Paik MD, Walgenbach-Bruenagel G, Kalff JC, et al. Lipofilling effects after breast cancer surgery in post-radiation patients: an analysis of results and algorithm proposal. *Eur J Plast Surg.* 2017;40:447-454.
16. Heine N, Eigenberger A, Brebant V, Kempa S, Seitz S, Prantl L, et al. The effect of radiotherapy on fat engraftment for complete breast reconstruction using lipofilling only. *Arch Gynecol Obstet.* 2023;307:549-555.