

## A MALIGNANT PHEOCHROMOCYTOMA IN A CHILD WITH VON HIPPEL-LINDAU MUTATION

GHEORGHE POPA<sup>1,2</sup>, CRISTINA LUCIA BLAG<sup>1,2</sup>, MĂDĂLINA BOTA<sup>1,2</sup>,  
ADRIANA ZOLOG

<sup>1</sup>Department of Pediatrics II, Children's Hospital Cluj-Napoca, Romania

<sup>2</sup>Department of Pediatrics II, Iuliu Hatieganu University of Medicine and Pharmacy, Cluj-Napoca, Romania

### Abstract

*Pheochromocytoma is a rare neuroendocrine tumor that arises from the chromaffin cells of the sympathetic nervous system. Over one third of pheochromocytomas are associated with germline mutations. We describe a 3 year-old girl with an inherited right adrenal malignant pheochromocytoma, with the mother diagnosed with von Hippel-Lindau syndrome. Genetic tests revealed the presence of the VHL c 244 C>G (p. Arg 82 Gly) heterozygote mutation in the mother, as well as in the child. After 6 months from the complete resection of the tumor, the patient is without any clinical symptoms, with normal blood pressure, normal ophthalmoscopy, no tumor markers and no evidence of tumor on cerebral or abdominal MRI. Lifelong complex follow-up is needed, as it is known that at a later age VHL mutation may cause retinal angiomas, cerebellar and spinal hemangioblastomas, relapsed pheochromocytoma, pancreatic and renal cysts, clear cell renal cell carcinoma and endolymphatic sac tumors.*

**Keywords:** malignant pheochromocytoma, von Hippel-Lindau mutation, child

### Background

Pheochromocytoma is a rare neuroendocrine tumor that arises from the chromaffin cells of the sympathetic nervous system, usually located in the adrenal medulla. Similar tumors from extra-adrenal areas are classified as paragangliomas [1]. They are characterized by secondary hypertension and may be detected by the study of the blood and urinary catecholamines [2].

Over one third of the pheochromocytomas are associated with germline mutations of known susceptibility genes belonging to the succinate dehydrogenase complex (SDHA, SDHB, SDHC, SDHD) or well characterized tumor syndromes: von Hippel-Lindau (VHL), Neurofibromatosis type 1 (NF1) and Multiple endocrine neoplasia type 2 (RET). Recently, three novel mutations have been described in the susceptibility genes SDHAF2, THEM 127 and MAX [3].

The variability of the clinical, pathological and genetic features makes every individual case of pheochromocytoma a diagnostic challenge and requires multidisciplinary management.

### Case report

A 3 year-old girl was admitted in the Department of Pediatric Oncology following several months history of febrile episodes, sweating and irritability. Symptoms were first interpreted as being of infectious causes, and that is why she received repeated antibiotic therapies. There was no improvement, and that is why more investigations were performed. An abdominal ultrasound performed in a pediatric hospital revealed a right adrenal tumor mass that prompted the transfer to our unit.

Family history: the patient's mother aged 38 was diagnosed with bilateral pheochromocytoma resected when she was the age of 18 years. She presented several relapses, the most recent one at the age of 32, when she was also

Manuscript received: 09.01.2017

Received in revised form: 22.02.2017

Accepted: 06.03.2017

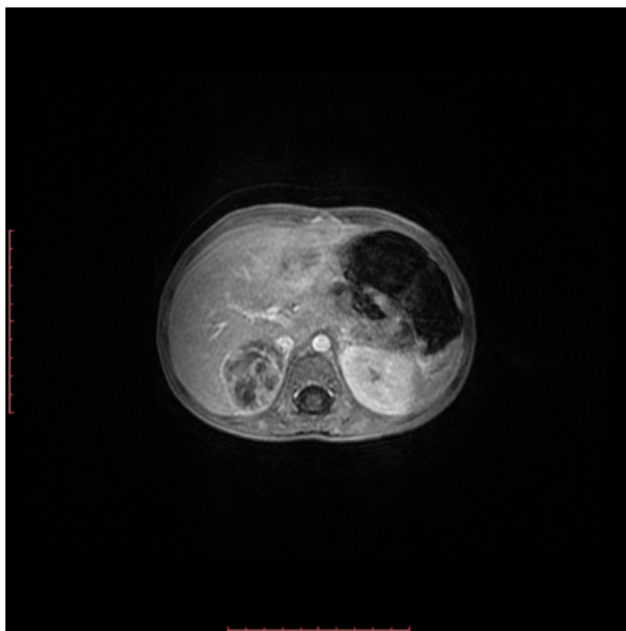
Address for correspondence: ghitapopa2000@yahoo.com

diagnosed with cerebral angioma. Genetic testing revealed the presence of the VHL c 244 C>G (p. Arg 82 Gly) heterozygote mutation, while the tests for RET, SDHB, SDHC and SDHD were negative.

The clinical examination of our patient revealed: pallor, paroxysmal febrile episodes with irritability and sweating, tachycardia (130/min), hypertension (170/126 mmHg). There was no palpable abdominal mass.

Abdominal ultrasound: well delimited tumor of the right adrenal gland, 37/34/35 mm in diameter, irregular with transonic inclusions.

Magnetic resonance imaging (MRI): right adrenal tumor, 35/42/43 mm in diameter, well delimited, irregular, with marked heterogenous contrast intake, presenting cystic and necrotic areas (Figure 1).



**Figure 1.** Right adrenal tumor.

Serum markers: urinary vanillylmandelic acid (VMA) 31.1 mg/24 h (normal <6.6), neuron specific enolase (NSE) 59.79 ng/ml (normal <17), ferritin 306.6 ng/ml (normal range 6-67), lactic dehydrogenase (LDH) 333 IU/L (normal range 125-300).

Genetic examination: VHL c 244 C>G (p. Arg 82 Gly) heterozygotic mutation.

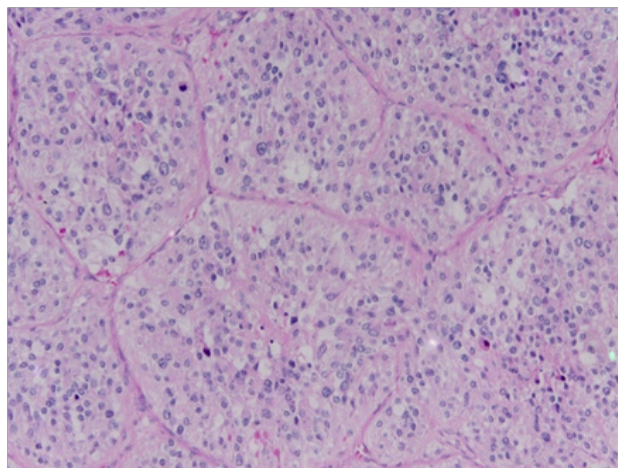
Management: Complete surgical resection was performed with special precautions, but it was uneventful and blood pressure instantly dropped to normal.

### Pathology

Macroscopic encapsuled 40/40/30 mm tumor, delimited by a bright yellow rim. The tumor is nodular with small hemorrhagic and necrotic areas.

Microscopy: adrenal gland is compressed by a well delimited tumor made by cell nests of variable dimensions, separated by a reduced vascular connective

stroma (Zellballen), with relatively numerous mitoses (8/10 High Power Field - HPF), most of them typical, very few atypical, extensive necrosis and vascular invasion. The aspect is suggestive for a malignant pheochromocytoma with Pheochromocytoma of the Adrenal gland Scaled Score (PASS) score 7: vascular invasion (1), necrosis (2), mitoses (2) (Figure 2).



**Figure 2.** Example of light microscopy image of sections from the excised tumor showing characteristics of malignant pheochromocytoma (Zellballen with central necrosis), hematoxylin eosin (HE) stain (10X).

### Outcome

After 6 months of follow-up, the patient is without any clinical symptoms, with normal blood pressure, no tumor markers, no evidence of tumor on cerebral and abdominal MRI and a normal ophthalmoscopy.

### Discussion

We describe a rare case of a pediatric right adrenal malignant pheochromocytoma inherited from a mother with von Hippel-Lindau syndrome.

Only 10% of pheochromocytomas are found in children, the median age of onset being 44 years with an annual incidence of 3-8 cases per 1 million per year in the general population [4].

Most of pheochromocytoma cases are benign but 17% are malignant [5]. In the absence of local invasiveness or distant metastases, histological discrimination is based on PASS over 4 [5]. In our reported case, PASS was 7, supporting the interpretation of malignancy.

Von Hippel-Lindau disease is an autosomal dominant inherited neoplastic disorder, occurring in about 50% of patients with an isolated familial pheochromocytoma caused by germline mutations in the VHL tumor suppressor gene that demonstrates marked phenotypic variability [6]. At a later age, it may cause retinal angiomas, cerebellar and spinal hemangioblastomas, relapsed pheochromocytoma, pancreatic and renal cysts, clear cell renal cell carcinoma and endolymphatic sac tumours [7].

### Conclusion

Our reported case provides evidence that von Hippel-Lindau syndrome may present very early in childhood as malignant pheochromocytoma. Such cases need complex multidisciplinary monitoring throughout the entire life for possible metastases and/or addition of new neoplastic lesions in many different parts of the body.

### References

1. De Lellis RA, Lloyd RV, Heitz PU, et al. Pathology and Genetics of Tumours of the Endocrine Organs, 3rd ed. Lyon France: IARC Press 2004. World Health Organization classification of tumours No. 8.
2. Guller U, Turek J, Eubanks S, Delong ER, Oertli D, Feldman JM. Detecting pheochromocytoma: defining the most sensitive test. *Ann Surg.* 2006;243:102-107.
3. Fishbein L, Nathanson KL. Pheochromocytoma and paraganglioma: understanding the complexities of the genetic background. *Cancer Genet.* 2012;205(1-2):1-11.
4. Kantorovich V, Pacak K. Pheochromocytoma and paraganglioma. *Prog Brain Res.* 2010;182:343-373.
5. Thomson LD. Pheochromocytoma of the Adrenal gland Scaled Score (PASS) to separate benign from malignant neoplasms: a clinicopathologic and immunophenotypic study of 100 cases. *Am J Surg Pathol.* 2002;26(5):551-566.
6. Maher ER, Neuman HP, Richard S. Von Hippel Lindau disease: a clinical and scientific review. *Eur J Hum Genet.* 2011;19(6):617-623.
7. Richard S, Graff J, Lindau J, Resche F. Von Hippel-Lindau disease. *Lancet.* 2004;363(9416):1231-1234.